e-ISSN: 2980-1389

JDSE

Journal of Dental Sciences and Education

MEDIHEALTH ACADEMY

Volume: 1

Issue: 3

Year: 2023

EDITOR-IN-CHIEF

Assoc. Prof. Dr. Elif Pınar BAKIR
Department of Restorative Dentistry, Faculty of Dentistry, Dicle University, Diyarbakır, TURKEY

ASSOCIATE EDITORS-IN-CHIEF

Assist. Prof. Dr. Merve YENİÇERİ ÖZATA
Department of Endodontics, Faculty of Dentistry, Dicle University, Diyarbakır, TURKEY

Assist. Prof. Dr. Zehra SUSGUN YILDIRIM
Department of Restorative Dentistry, Çukurova University, Adana, TURKEY

EDITORS

Assist. Prof. Dr. Eyyüp ALTINTAŞ
Department of Protesthetic Dentistry, Faculty of Dentistry, Fırat University, Elazığ, TURKEY

Spec. Dr. Yeşim AYLA
Department of Endodontics, Kapadokya University, Faculty of Dentistry, Nevşehir, TURKEY

EDITORIAL BOARD

Assist. Prof. Dr. Abdurrahman YALÇIN
Department of Restorative Dentistry, Faculty of Dentistry, Batman University, Batman, TURKEY

Assist. Prof. Dr. Ayşe RENÇBER
Department of Protesthetic Dentistry, Faculty of Dentistry, Fırat University, Elazığ, TURKEY

Spec. Dr. Candan AYDIN HOŞ
Department of Restorative Dentistry, Faculty of Dentistry, Bolu Abant İzzet Baysal University, Bolu, TURKEY

Assist. Prof. Dr. Cansu YIKICI
Department of Restorative Dentistry, Faculty of Dentistry, Lokman Hekim University, Ankara, TURKEY

Assist. Prof. Dr. Demet Süer TÜMEN
Department of Orthodontics, Faculty of Dentistry, Dicle University, Diyarbakır, TURKEY

Spec. Dr. Diler DENİZ
Department of Prosthetic Dentistry, Faculty of Dentistry, Hacettepe University, Ankara, TURKEY

Assist. Prof. Dr. Ebru AKLEYİN
Department of Pediatric Dentistry, Dicle University, Faculty of Dentistry, Diyarbakır, TURKEY

Assist. Prof. Dr. Emin Caner TÜMEN
Department of Pediatric Dentistry, Faculty of Dentistry, Dicle University, Diyarbakır, TURKEY

Prof. Dr. Filiz ACUN KAYA
Department of Periodontology, Faculty of Dentistry, Fırat University, Elazığ, TURKEY

Assist. Prof. Dr. Kübra Yıldız DOMANİÇ
Department of Prosthetic Dentistry & Dental Prosthesis Technology Programme, Vocational School of Health Services, Fenerbahçe University, İstanbul, TURKEY

Assist. Prof. Dr. Melek ATİLLE
Department of Periodontology, Faculty of Dentistry, Fırat University, Elazığ, TURKEY

Assist. Prof. Dr. Mustafa Orkun ERTUĞRUL
Department of Restorative Dentistry, Faculty of Dentistry, Atlas University, İstanbul, TURKEY

Assist. Prof. Dr. Nurullah DÜĞER
Department of Periodontology, Faculty of Dentistry, Fırat University, Elazıg, TURKEY

Assist. Prof. Dr. Ömer CELLİK
Department of Restorative Dentistry, Faculty of Dentistry, Adıyaman University, Adiyaman, TURKEY

Prof. Dr. S. Zelal ÜLKÜ
Department of Protesthetic Dentistry, Faculty of Dentistry, Dicle University, Diyarbakır, TURKEY

Assist. Prof. Dr. Savaş SAĞMAK
Department of Restorative Dentistry, Faculty of Dentistry, Adıyaman University, Adiyaman, TURKEY

Spec. Dr. Seda FALAKALOĞLU
Department of Endodontics, Faculty of Dentistry, Afyonkarahisar Health Sciences University, Afyon, TURKEY

Assist. Prof. Dr. Sema YAZICI AKBIYIK
Department of Restorative Dentistry, Faculty of Dentistry, Lokman Hekim University, Ankara, TURKEY

Assist. Prof. Dr. Şeyhmus BAKIR
Department of Restorative Dentistry, Faculty of Dentistry, Dicle University, Diyarbakır, TURKEY

Assist. Prof. Dr. Sinem COŞKUN
Department of Oral And Maxillofacial Radiology, Faculty of Dentistry, Lokman Hekim University, Ankara, TURKEY

LANGUAGE EDITOR

Assoc. Prof. Dr. Esra GÜZEL TANOĞLU
Department of Molecular Biology and Genetics, Institute of Health Sciences, University of Health Sciences, İstanbul, TURKEY

STATISTICS EDITOR

Assoc. Prof. Dr. Turgut KÜLTÜR
Department of Physical Therapy and Rehabilitasyon, Faculty of Medicine, Kırıkkale University, Kırıkkale, TURKEY

Dear Colleagues,

It is with great pleasure that I welcome you to the third issue of our peer-reviewed academic journal named, Journal of Dental Sciences and Education (JDSE). In this third issue, reviews of new developments in the field of dentistry and original researchs are included. One of our most important goals is to mediate appropriately the sharing of knowledge and experience among dental professionals, researchers and academicians. In this issue, we share with you six articles covering various topics in dentistry.

Our first article of the journal "Evaluation of biocompatibility of four different one-step self-etching adhesives by animal experimental method" is an original article and the authors aimed to compare the biocompatibility of four different single-stage self-etch adhesive materials with the animal test method and evaluate them histopathologically. The second article "Investigation of the effects of embedded third molar to the second molar through CBCT and panoramic radiography" is an original article. The authors have evaluated the correlation between these two methods by comparatively examining the caries, external root resorption, and periodontal bone destruction caused by impacted third molars on adjacent teeth by comparing panoramic and CBCT images. The third article "Prevalence of elongated styloid process on cone-beam computed tomographic images: a retrospective study" is an invitro study evaluated to the prevalence and the morphometric features of the styloid process (SP) via cone-beam computed tomography (CBCT). The fourth article, "In vitro effect of different cleaning procedures of AH plus on microtensile bond strength of immediate or delayed restoration" is an original article about effect cleaning procedures of AH Plus on bond strength. The fifth article "Short dental implants" another a review article. Finally, the sixth article "Gingival crevicular fluid and peri-implant sulcus fluid" is a review article. The authors argue that understanding GCF components will help elucidate the initiating events in the pathogenesis of periodontal and peri-implant diseases and pursue effective treatment paradigms and strategies of the disease process for the prevention of periodontal and peri-implant diseases.

I would like to thank the authors, reviewers, editorial team and publisher for their hard work and dedication in bringing this third issue to fruition. We look forward to providing you with the latest insights and developments in dentistry, and we welcome your feedback and suggestions.

Sincerely,

Assoc. Prof. Dr. Elif Pınar BAKIR, PhD
Editor-in-Chief

Journal of
Dental Sciences
and Education

CONTENTS

Volume: 1 Issue: 3 Year: 2023

ORIGINAL ARTICLES

Prevalence of elongated styloid process on cone-beam computed tomographic images: a retrospective study 61-65
Katı E.

Investigation of the effects of embedded third molar to the second molar through cbct and panoramic radiography 66-80
Kısa H, Bakır EP.

Evaluation of biocompatibility of four different one-step self-etching adhesives by animal experimental method 81-89
Aydın MS, Bakır Ş, Bakır E.

In vitro effect of different cleaning procedures of ah plus on microtensile bond strength of immediate or delayed restoration 90-94
Kölüş T, Kahveci Ö.

REVIEWS

Short dental implants 95-97
Hendek MK, Barış K, Olgun E.

Gingival and periodontal diseases in children 98-100
Hendek MK, Barış K, Olgun E.

Journal of Dental Sciences and Education

Original Article

DOI: 10.51271/JDSE-0012

Prevalence of elongated styloid process on cone-beam computed tomographic images: a retrospective study

Ezgi Katı

Department of Dentomaxillofacial Radiology, Faculty of Dentistry, Hacettepe University, Ankara, Turkey

Cite this article: Katı E. Prevalence of elongated styloid process on cone-beam computed tomographic images: a retrospective study. *J Dent Sci Educ.* 2023;1(3):61-65.

Corresponding Author: Ezgi Katı, sahinkayaezgi@gmail.com

Received: 07/06/2023 ◆ **Accepted**: 26/06/2023 ◆ **Published**: 30/09/2023

ABSTRACT

Aims: The aim of the study was to evaluate the prevalence and the morphometric features of the styloid process (SP) via cone-beam computed tomography (CBCT).

Method: 400 SP of 200 individuals (92 males, 108 females, age range 12-81) were examined retrospectively in CBCT images in the axial, sagittal, and coronal planes. The measurements of SP and clinical and incidental findings associated with styloid ligament elongation (SPE) were detected. For descriptive statistics, the mean and standard deviation are given for numerical variables. The Mann-Whitney U test was used for measurements. The consistency of right and left SP lengths was analyzed for normality using the Shapiro-Wilk test ($p<0.05$).

Results: Males (55.7%) had a substantially higher prevalence of ESP than females (33.1%) ($p=0.032$). On the right side of the SP, the mean length was 26,76 mm (range: 8,7-63,3 mm), while on the left, it was 26,61 mm (range: 5,8-55,9 mm). 51 of them had bilateral lengths greater than 30 mm. The eight symptomatic patients' CBCT scans revealed SP sized anywhere from 36,6 mm to 69 mm on the right side. As incidental findings, soft tissue calsifications were detected in 5% of the 200 patients.

Conclusion: Men were found to have a higher prevalence of SPE than women, and a tiny percentage of cases were asymptomatic. There was no significant difference between right- and left-sided SP.

Key words: Calsification, cone-beam computed tomography, eagle syndrome

INTRODUCTION

The styloid process is an anatomical structure shaped like a cylindrical, thin, needle-like projection of varying lengths, averaging 2 to 3 cm.[1] It is classified as elongated if the measurement is more than 30 mm.[2] The styloid process (SP) projects from the inferior portion of the petrous temporal bone and offers attachment to the stylohyoid ligament and the muscles attached to the SP. Through these structures, SP facilitates the movement of the surrounding structures, such as the tongue, pharynx, larynx, hyoid bone, and mandible. Significant vessels and nerves surround the SP. The vena jugularis interna, arteria carotis interna, and some important cranial nerves lie medially to the SP. Arteria occipitalis and nervus hypoglossus run along its lateral side.[3]

The stylomastoid foramen, where the nervus facialis emerges from the skull, is directly posterior to the SP; however, it passes lateral to the process as it pierces through the parotid gland prior to splitting into its subsequent branches.[4,5]

The structure shows variations in length, angulation, and other morphological features between individuals. The length of the styloid processes might also be different bilaterally within the same individual.[6]

Multiple theories have been laid out as the etiology responsible for the variance in ossification and elongation of SP. The first theory is the "theory of reactive hyperplasia". The second theory is the "theory of reactive metaplasia,". The third theory is the "theory of anatomic variance." An additional and fourth theory is that the elongated styloid process is due to retained embryologic tissue from Reichert's cartilage.[7]

Although these theories explain the ossification and elongations in different ways, a consensus has not been established.

The frequent presence of an elongated styloid process (SPE) is estimated at around 4% of the general population. Compared to men, women are more likely to have SPE.[5]

SPE may be a result of various clinical symptoms, such as pain in the neck and cervicofacial area. Although these physiological differences are often found incidentally, some patients might develop a constellation of symptoms known as Eagle syndrome. The symptomatology of Eagle syndrome occurs secondary to irritation and/or compression of surrounding structures from an abnormal SP.[3]

Despite the fact that the majority of these individuals have no symptoms, a small percentage of those with SPE show

This work is licensed under a Creative Commons Attribution 4.0 International License.

symptoms and can present with one of two types of Eagle syndrome.[7,8]

Eagle syndrome presents itself with various degrees of symptoms, such as a sharp pain in the neck or the ear that extends to the maxilla, face, and oral cavity. Moreover, it might also be correlated with vertigo, tinnitus, or a sensation of something abnormal in the pharynx. Symptoms of classic Eagle syndrome are usually unilateral but can rarely present bilaterally. Pressure on the arteria carotis interna might present with symptoms of internal carotid vascular insufficiency such as weakness, visual changes, or syncope exacerbated with head movement. The SPE might also pose the risk of carotid artery dissection, resulting in a stroke or transient ischemic attack.[9]

The diagnosis of Eagle syndrome depends on the patient's clinical presentation, radiological investigation, and lidocaine infiltration test.[5]

For radiological investigations, a lateral head and neck X-ray, a Towne radiograph, can identify the SPE in two-dimensional imaging. Computed tomography (CT) allows for the radiological examination and measurements of the SP three-dimensionally.[10,11]

In the near past, three-dimensional cone-beam computerized tomography (CBCT) was a trustworthy imaging tool for anatomical structures of the maxillofacial region with high image quality, diagnostic accuracy, and sensitivity.[12,13]

The purpose of the present study was to appraise the size of the styloid process, the prevalence of an elongated styloid ligament, its relation to sex, location, and correlation between the right and left sides using CBCT images.

METHODS

The radiographic images of 200 individuals who had been referred to the oral and maxillofacial radiology department for CBCT examination from September 2021 to August 2022 were evaluated retrospectively.

In this retrospective study, 200 CBCT images of patients who were randomly selected and aged from 12 to 81 years were analyzed. The study was carried out in the Department of Oral And Maxillofacial Radiology of Lokman Hekim University's Faculty of Dentistry. All the CBCT examinations were acquired with Newtom VGI-Evo (NewTom, Verona, Italy) and reconstructed with NNT® software (NewTom®, v. 5.6.0) with a 0.300 mm axial pitch and 0.300 mm axial thickness. The measurements were accomplished utilizing InVivo Dental Application Version 5.2.3 (Anatomage, Santa Clara, USA). Only high-quality images were included in the study. Any radiograph with questionable SP and images of low quality, such as scattering or insufficient accuracy of bony borders, was excluded from the study. The study protocol, numbered 2022/201, was approved by the Scientific Research Ethics Committee at Lokman Hekim University. The study's protocol was carried out according to the principles described in the Declaration of Helsinki, including all amendments and revisions. The assessment of images was fulfilled directly on the monitor screen (a 23-inch Acer 1920 x 1080 pixel HP Reconstruction monitor).

Radiological measurements of 400 SPs were performed on CBCT images of the 200 patients by an oral and maxillofacial radiologist. The length and type of SP were recorded separately for each side since there were some differences between the right and left sides in the images. SP were assessed based on their average lengths. The length of the SP was recorded from the caudal margin on the tympanic plate to the tip of the process for each side. If the cranial part of the SP was not suitable for measurement, the length between the probable attachment point to the calvaria and the tip of the SP was recorded (14). The length of SP >30 mm was recorded as unilateral or bilateral elongation.[2,5-21]

Statistical Analysis

The consistency of right and left styloid process lengths obtained from the subjects was analyzed for normality using the Shapiro-Wilk test. Neither of the measurements was found to be normally distributed among the study group. The presentation of descriptive studies used average ± standard deviation, and median presentation. The differences between the ages of the subjects according to gender were analyzed using the Student's t-test. A Mann-Whitney U test was used to analyze the difference between right and left styloid process length according to gender. A Kruskal-Wallis variance analysis was used to compare right and left styloid process length according to age groups. Spearman's rank correlation coefficient was calculated for the correlation between age and styloid process lengths. SPSS (version 21.00 for Windows. SPSS Inc., Chicago, IL, USA) was used for statistical analysis. ($p < 0.05$)

RESULTS

A total of 200 individuals, 108 women and 92 men, between the ages of 12 and 81, with a mean age of 41,32±18,76 were selected for the research. (**Table 1**)

Table 1. Descriptive Analysis

	N	Minimum	Maximum	Mean	Std. Deviation
Age	200	12	81	41.32	18.769
Valid N (listwise)	200				

Examination of CBCT images demonstrated that the mean length of the styloid processes was 26,7 ± 8,3 mm (range: 8.7-63.3 mm) on the right side and 26,6 ± 7,7 mm (range: 5,8-55.9 mm) on the left side. The prevalence of ESP was significantly higher in males (55.7%) than females (33.1%). The consistency of right and left styloid process lengths obtained from the subjects was analyzed for normality using the Shapiro-Wilk test ($p = 0.032$). (**Table 2**).

Table 2. Test of Normality

Gender	Shapiro-Wilk		
	Statistic	df	Sig.
Female	.900	108	.32
Right ligament			
Male	.941	92	.169
Female	.842	108	.002
Left ligament			
Male	.931	92	.096

The results for the ligaments on each side were similar in both genders. ($p=0.176 > 0.05$) (**Table 3**)

As incidental findings, 10 of 200 individuals had soft tissue calsifications. (**Figure 1**)

51 of the styloid processes were longer than 30 mm bilaterally. (**Figure 2**)

Table 3. Paired Samples Test for SP between right and left side

	Mean	N	Std. Deviation
Right ligament	26.768	200	8.3125
Pair	26.613	200	7.7162
Left ligament			.176

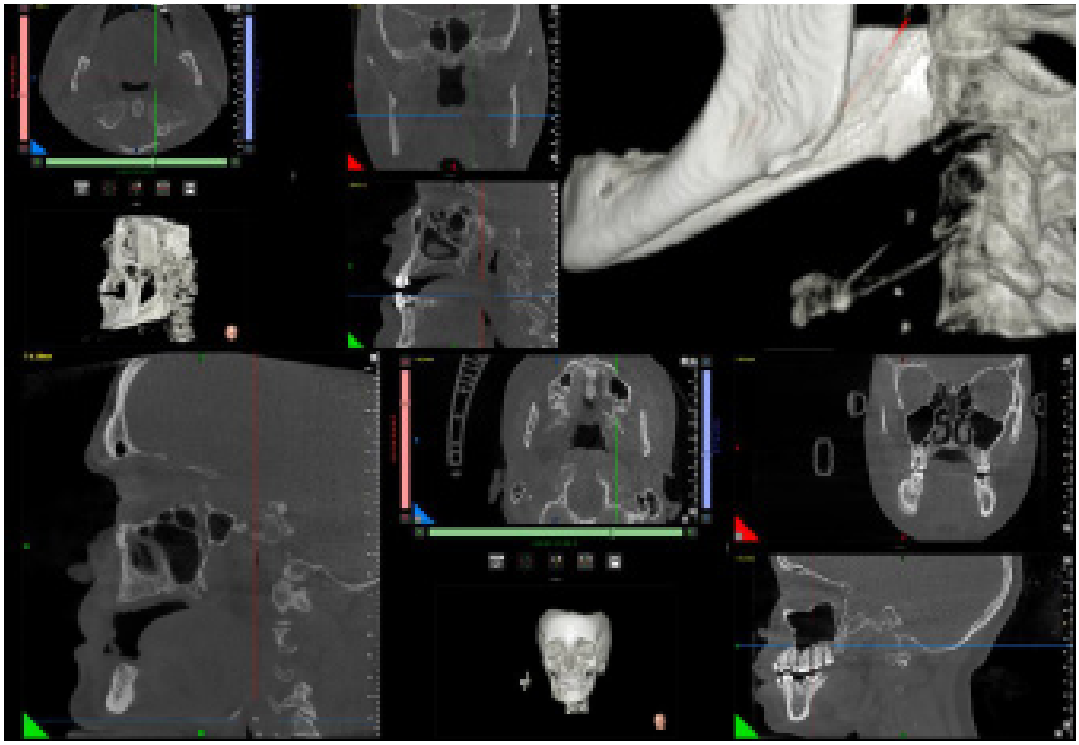

Figure 1. CBCT Image of soft tissue calsifications. Tonsillolith, carotis artery calsifications, anthrolith.

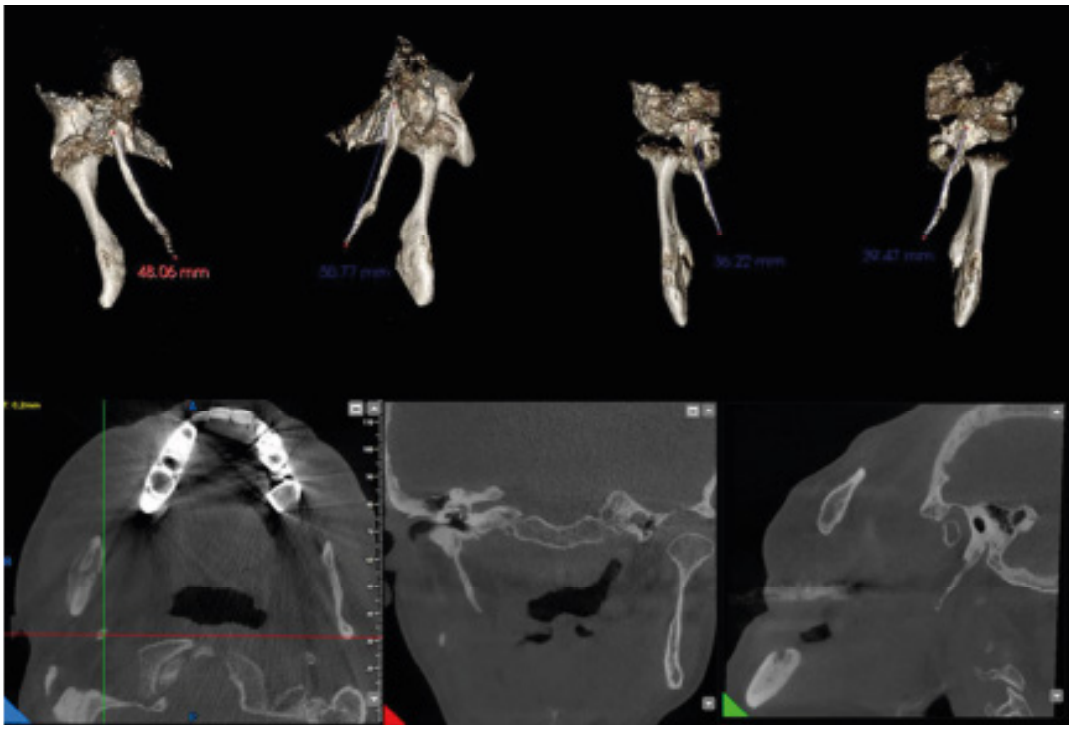

Figure 2. Coronal, axial and sagittal views of CBCT image.

Only eight patients were symptomatic. The CBCT images of the symptomatic patients showed styloid processes measuring at least 36,6 mm to 69 mm on the right side. (**Figure 3**)

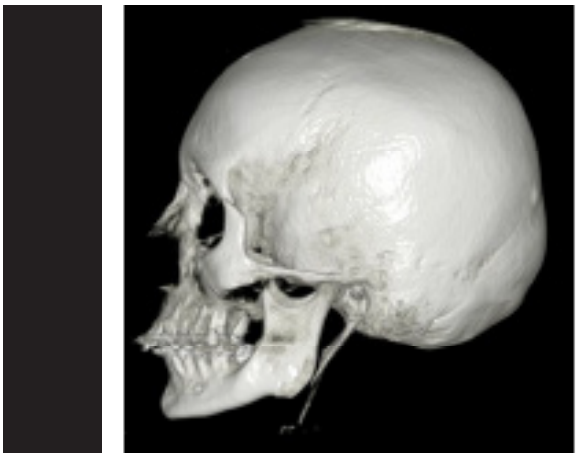

Figure 3. CBCT image of a SP measuring 69 mm.

DISCUSSION

There are several variations of features of the SP, such as the length, the degree of ossification, the distrubution between genders, and the right and left sides.[22]

The hyoid smaller horn, SP, and stylohyoid ligament are formed from Reichert's cartilage during the development of the head and neck region. In some cases, ossification of the stylohyoid ligament occurs and leads to the formation of SPE. The definition of Eagle's syndrome is symptomatic lengthening of the SP or calcification of the stylohyoid and stylomandibular ligaments.[15]

Physical examination and radiographic analysis are both used to make a diagnosis. There are several radiographic techniques used in dentistry to diagnose SPE, such as orthopantomographs and cone beam computed tomography.[21,22,23-26]

In this study, CBCT images of 200 individuals were examined. Only a tiny part (between 4% and 10.3%) of those with SPEs, who represent roughly 4% of the population, are considered to show symptoms.[27]

Öztunç et al.[23] compared elongated SP and without elongated SP on CBCT images and found the mean age of the patients with SPE to be 47.28 ± 12.4 years. In this study, the mean age of the patients with SPE was 41,32 ± 18,76 years (range: 12–81 years), and similar to this, all of the symptomatic patients were older than .[40]

Similar to this study, other studies have found that the mean SP length was significantly different between males and females. The prevalence of SPE was higher in males than females.[21,25,28]

Camarda et al.[29] measured the mean length of the SP in their study, and it was similar to this study. And also, the values of both sides were found to be close to each other, similar to the present study. There was no difference between both sides in both genders in the present study.

Jung et al.[30] examined panoramic images of 1000 patients and reported that both sides' distributions are similar and do not significantly differ (Kolmogorov–Smirnov test, P= 0.380). Although the examined image technique differs between 2 and 3 dimensions, both studies showed similar results.

Clinical complaints of SPE are related to the size of the stylohyoid complex.[19] In this study, the CBCT images of the eight symptomatic cases showed SP measuring at least 36,6 mm to 69 mm on the right side. Camarda et al.[19] reported that patients experiencing symptoms tended to be older than 40 and had no recent history of cervicopharyngeal trauma, tonsillectomy, or other surgery. Nobody among our symptomatic individuals had ever undergone surgery or experienced trauma.

Soft tissue calsifications such as tonsilloliths, antroliths, and carotid artery calsifications were detected as incidental findings.

Missias et al.[31] detected soft tissue calsifications in CBCT images with different fields of view. SPE and tonsillolith were the most frequent calcifications in their study. Pette et al.[32] evaluated the prevalence of soft tissue calcifications in 318 samples and reported that tonsillolithes and antrolithes were common with a range of 32% and 3%, respectively. Price et al.[33] evaluated incidental findings in the maxillofacial region by CBCT and reported tonsilloliths, antroliths, and carotid artery calcifications at 43%, 5%, and 13% in CBCT scans of 300 individuals, respectively.

In the present study, 10 of 200 individuals had soft tissue calsifications. Tonsilloliths (4 of 10 individuals) located on the right side of the lateral wall of the pharynx were sized at 0.8mm, 1,8 mm, 1,4 mm, 1,3 mm, and 0,7 mm in diameter. Soft tissue calsifications (3 of 10 individuals) located in the laryngopharynx sized 1,7 mm, 0,8 mm, and 0,5 mm in diameter. Antrolith (1 of 10) sized 2 mm in diameter and mucosal thickening consistent with maxillary sinusitis. The elongated styloid process might also compress the carotid artery. In this study, a CBCT image showed carotid artery calcifications (2 of 10 individuals) sized 2,0 and 2,2 mm in diameter.

CONCLUSION

In this study, morphometric examination of the styloid process, clinical complaints, and potential incidental findings were all assessed using CBCT images. While the prevalence of SPE was found to be higher in men compared to the female population, no significant difference was found for right- and left-sided SP.

ETHICAL DECLARATIONS

Ethics Committee Approval: The study protocol, numbered 2022/201, was approved by the Scientific Research Ethics Committee at Lokman Hekim University.

Informed Consent: Because the study was designed retrospectively, no written informed consent form was obtained from patients.

Referee Evaluation Process: Externally peer-reviewed.

Conflict of Interest Statement: The authors have no conflicts of interest to declare.

Financial Disclosure: The authors declared that this study has received no financial support.

Author Contributions: All of the authors declare that they have all participated in the design, execution, and analysis of the paper, and that they have approved the final version.

REFERENCES

1. Glogoff MR, Baum SM, Cheifetz I. Diagnosis and treatment of Eagle's Syndrome. *J. Oral Surg.* 1981;39(12):941-944.
2. Murtagh RD, Caracciolo JT, Fernandez G. CT findings associated with Eagle syndrome. Am J Neuroradiol. 2001;22(7):1401-1412.
3. Abuhaimed AK, Alvarez R, Menezes RG. Anatomy, Head and Neck, Styloid Process. 2022 Jan 14. In: StatPearls [Internet]. Treasure Island (FL): StatPearls Publishing; 2022 Jan–. PMID: 31082019.
4. Vadgaonkar R, Murlimanju BV, Prabhu LV, et al. Morphological study of styloid process of the temporal bone and its clinical implications. *Anat Cell Biol.* 2015;48(3):195-200.
5. Piagkou M, Anagnostopoulou S, Kouladouros K, Piagkos G. Eagle's syndrome: a review of the literature. *Clin Anat.* 2009;22(5):545-558.
6. Custodio AL, Silva MR, Abreu MH, Araújo LR, de Oliveira LJ. Styloid process of the temporal bone: morphometric analysis and clinical implications. *Biomed Res Int.* 2016;2016:8792725.
7. Badhey A, Jategaonkar A, Anglin Kovacs AJ, Kadakia S, De Deyn PP, Ducic Y, et al. Eagle syndrome: a comprehensive review. *Clin Neurol Neurosurg.* 2017;159:34-38.
8. Moon CS, Lee BS, Kwon YD, et al. Eagle's syndrome: a case report. *J Korean Assoc Oral Maxillofac Surg.* 2014;40(1):43-47.
9. Kamal A, Nazir R, Usman M, Salam BU, Sana F. Eagle syndrome; radiological evaluation and management. *J Pak Med Assoc.* 2014;64(11):1315-1317.
10. Nayak DR, Pujary K, Aggarwal M, Punnoose SE, Chaly VA. Role of three-dimensional computed tomography reconstruction in the management of elongated styloid process: a preliminary study. *J Laryngol Otol.* 2007;121(4):349-353.
11. Petrović B, Radak D, Kostić V, Covicković-Sternić N. Styloid syndrome: a review of literature. *Srp Arh Celok Lek.* 2008;136(11-12):667-674.
12. Scarfe WC, Farman AG, Sukovic P: Clinical applications of cone-beam computed tomography in dental practice. *J Canadian Dental Assoc.* 2006;72(1):75-80.
13. White SC, Pharoah MJ. White and Pharoah's Oral Radiology: Principles and Interpretation. 8th ed. St. Louis, Missouri: Elsevier Mosby;2018. 185-199.
14. Paparella MM, Shumrick DA. Otolaryngology Philadelphia. 2nd ed. Saunders: Elsevier;1980.
15. Correll RW, Jensen JL, Taylor JB, Rhyne RR. Mineralization of the stylohyoid-stylomandibular ligament complex. A radiographic incidence study. *Oral Surg Oral Med Oral Pathol.* 1979;48(4):286-291.
16. Keur JJ, Campbell JP, McCarthy JF, Ralph WJ. The clinical significance of the elongated styloid process. *Oral Surg Oral Med Oral Pathol* 1986;61(4):399-404.
17. Langlais RP, Miles DA, Van Dis ML. Elongated and mineralized stylohyoid ligament complex: a proposed classification and report of a case of Eagle's syndrome. *Oral Surg Oral Med Oral Pathol* 1986;61(5):527-532.
18. Sekerci AE, Soylu E, Arikan MP, Aglarci OS. Is there a relationship between the presence of ponticulus posticus and elongated styloid process? *Clin Imaging.* 2015;39(2):220-224.
19. Anbiaee N, Javadzadeh A. Elongated styloid process: Is it a pathologic condition? *Indian J Dent Res.* 2011;22(5):673-677.
20. Prasad KC, Kamath MP, Reddy KJ, Raju K, Agarwal S. Elongated styloid process (Eagle's syndrome): A clinical study. *J Oral Maxillofac Surg.* 2002;60(2):171-175.
21. Donmez M, Okumus O, Pekiner FN. Cone beam computed tomographic evaluation of styloid process: A retrospective study of 1000 patients. *European J Dentistry.* 2017;11(02):210-215.
22. İlgüy M, İlgüy D, Güler N, Bayirli G. Incidence of the type and calcification patterns in patients with elongated styloid process. *J Int Med Res.* 2005;33(1):96-102.
23. Öztunç H, Evlice B, Tatli U, Evlice A. Cone-beam computed tomographic evaluation of styloid process: a retrospective study of 208 patients with orofacial pain. *Head & Face Med.* 2014;10(1):1-7.
24. Tijanić M, Burić N, Burić K. The use of Cone Beam CT (CBCT) in differentiation of true from mimicking Eagle's syndrome. *Int J Environ Res Public Health.* 2020;17(16):5654.
25. Buyuk C, Gunduz K, Avsever H. Morphological assessment of the stylohyoid complex variations with cone beam computed tomography in a Turkish population. *Folia morphologica* 2018;77(1):79-89.
26. Javadian Langaroodi A, Hoseini Zarch SH, Rahpeyma A, Ebrahimnejad H, Arezoobakhsh A, Sanaei A. Assessment of stylohyoid ligament in patients with Eagle's syndrome and patients with asymptomatic elongated styloid process: A cone-beam computed tomography study. *Journal of Oral Health and Oral Epidemiology.* 2016;5(4):215-220.
27. Rechtweg JS, Wax MK. Eagle's syndrome: a review. *Am J Otolaryngol* 1998;19(5):316-321.
28. Nalçacı R, Mısırlıoğlu M. Yaşlı Bireylerde stiloid proçesin radyolojik olarak değerlendirilmesi. *AÜ Diş Hekimliği Fakültesi Derg.* 2006;3(1):1-6.
29. Camarda AJ, Deschamps C, Forest DI. Stylohyoid chain ossification: a discussion of etiology. *Oral Surg Oral Med Oral Pathol.* 1989;67(5):508–514.
30. Jung T, Tschernitschek H, Hippen H, Schneider B, Borchers L. Elongated styloid process: when is it really elongated?. *Dentomaxillofacial Radiology.* 2004;33(2):119-124.
31. Missias EM, Nascimento EHL, Pontual MLA, Pontual AA, Freitas DQ, Perez DEC, Ramos- Perez FMM. Prevalence of soft tissue calcifications in the maxillofacial region detected by cone beam CT. *Oral Diseases.* 2018;24(4):628-637.
32. Pette GA, Norkin FJ, Ganeles J, et al. Incidental findings from a retrospective study of 318 cone beam computed tomography consultation reports. *Int J Oral Maxillofac Implants.* 2012;27(3):595-603.
33. Price JB, Thaw KL, Tyndall DA, Ludlow JB, Padilla RJ. Incidental findings from cone beam computed tomography of the maxillofacial region: a descriptive retrospective study. *Clin Oral Implants Res.* 2012;23(11):1261-1268.

Journal of Dental Sciences and Education

Original Article

DOI: 10.51271/JDSE-0013

Investigation of the effects of embedded third molar to the second molar through CBCT and panoramic radiography

Hazal Kısa[1], Elif Pınar Bakır[2]

[1]Tarsus Oral and Dental Health Center, Mersin, Turkey
[2]Department of Restorative Dentistry, Faculty of Dentistry, Dicle University, Diyarbakır, Turkey

Cite this article: Kısa H, Bakır EP. Investigation of the effects of embedded third molar to the second molar through CBCT and panoramic radiography. *J Dent Sci Educ*. 2023;1(3):66-80.

Corresponding Author: Elif Pınar Bakır, elifpinarbakir@gmail.com

Received: 01/09/2023 ◆ **Accepted**: 29/09/2023 ◆ **Published**: 30/09/2023

ABSTRACT

Aims: The aim of this study is to evaluate the correlation between these two methods by comparatively examining the caries, external root resorption, and periodontal bone destruction caused by impacted third molars on adjacent teeth by comparing panoramic and CBCT images.

Methods: In this study, all the OPG and CBCT images of 388 impacted third molars belonging to 205 patients were evaluated. While impacted third molars were differentiated according to Pell & Gregory and Archer and Kruger classification criteria, distal caries, marginal bone loss, and external root resorption in the second molar were examined by panoramic and CBCT.

Results: 388 impacted teeth were evaluated in 205 patients, and the rate of distal caries was 27.5% in panoramic radiographs and 31% in CBCT ($p<0.05$). External root resorption formation in second molars observed in CBCT was not observed in 18.8% of panoramic radiographs ($p<0.05$). Marginal bone loss was observed 9.8% more in CBCT than in panoramic x-rays ($p<0.05$). All three pathologies were observed at the highest rate in the Class 2 position, while distal caries was observed at the highest rate in position B. In the examinations performed for the lower and upper jaws, the rate of all three pathologies was found to be higher in the CBCT evaluation than in the panoramic radiography.

Conclusion: CBCT; Although it is disadvantageous in terms of radiation dose and cost, it has been found to be more effective than panoramic x-ray in the detection of distal caries, marginal bone loss, and external root resorption pathologies. It is thought that this situation can be considered as a criterion in terms of profit-loss analysis when the examination is requested, thus preventing pathologies from being overlooked.

Keywords: Impacted molar tooth, distal caries, external root resorption, marginal bone loss, CBCT, panoramic radiography

INTRODUCTION

Impacted teeth are teeth that are completely or partially covered by mucosa and bone for more than two years after a physiologic eruption. In the permanent dentition, mandibular third molars are most commonly impacted, followed by maxillary third molars. Impacted third molars may cause caries lesions and resorption in adjacent teeth, periodontal disease, marginal bone loss on the root surface of adjacent teeth, and cysts or tumors.[1,2] Caries and resorption caused by impacted third molars in second molars sometimes require removal of the third molar and restoration of its defect. Early detection and evaluation of the caries risk of second molars associated with second molars can help in the prevention of distal caries in second molars.[3]

Panoramic radiography is the most commonly used imaging technique for the evaluation of impacted teeth and related lesions. However, it may not be sufficient in most cases. CBCT can detect periodontal diseases, caries, and root resorption at the initial stage.[4]

The aim of this study was to examine these pathologies comparatively with panoramic and CBCT and to evaluate the correlation between the two methods. In addition, this study aimed to examine the prevalence of distal caries, external root resorption, and marginal bone loss, the classification of impacted third molars, and the effects of these groups on pathologies in adjacent second molars.

METHODS

The ethics committee approval required for the study, which was conducted at Dicle University Faculty of Dentistry, Department of Restorative Dental Treatment, was evaluated at the Dicle University Faculty of Dentistry Ethics Committee meeting dated 28.04.2021, numbered 4, and the decision was taken with the meeting decision with protocol number 2021/27. This study was produced from the specialty thesis titled "Investigation Of The Effects Of Embedded Third

This work is licensed under a Creative Commons Attribution 4.0 International License.

Molar To The Second Molar Through CBCT And Panoramic Radiography" prepared by Hazal Kısa, a dental specialty student in Dentistry, and supervised by Assoc. Prof. Dr. Elif Pınar Bakır. All procedures were carried out in accordance with the ethical rules and the principles of the Declaration of Helsinki.

Acquisition of the Images Included in The Study

The images used in the study were obtained from the archived OPG and CBCT images of male and female patients who applied to Dicle University Faculty of Dentistry, The Department of Oral and Maxillofacial Radiology for reasons such as trauma, impacted teeth, lesion treatment, and orthodontic treatment.

Study Inclusion Criteria

Archival images were evaluated for compliance with some criteria. The main criteria for our study were the presence of OPG and CBCT images of patients aged 16 years and older and that these images were taken on the same day, the presence of fully or partially impacted third molars, and the presence of a second molar in one or more adjacent areas. Third molars with incomplete root tip closure, images with generalized bone destruction, and images with restorations or large cavitations distal to the second molars were excluded. Images of patients with intraosseous pathologies originating from third molars or trauma patients were excluded. In addition, images that could not be examined properly due to artifacts or positioning errors due to dense materials such as brackets, metal pins, or mini-screws were excluded.

In our study, all OPG and CBCT images of 388 impacted third molars in 205 patients were evaluated by the first observer with 3 years of experience. In addition to the Pell & Gregory classification, the impacted third molars were classified according to the criteria of the Archer & Kruger classification, and the effects on the second molar were analyzed. The presence of distal caries and external bone resorption was examined on both OPG and CBCT images, and bone destruction in the distal region of the second molar was measured. The images in the group of randomly selected patients were then independently evaluated by a second observer with 21 years of experience. The data analyzed by both observers was entered into data forms separately for OPG and CBCT.

Technical Specifications of the CBCT and Panoramic Device Used and Conditions For Evaluating Images

CBCT images obtained with a three-dimensional cone beam computed tomography device (i-CAT®, Model 17-19, Imaging Sciences International, Hatfield, Pa., USA) were analyzed with the i-CAT imaging program of the same company.

Panoramic radiographs were obtained using a digital panoramic radiography device called the Midmark Vantage (Midmark, Ohio, USA). Images were acquired in standard acquisition mode (66 kV, 6 mA, 16 s). The evaluation was performed under appropriate lighting, and the images were analyzed using the Metasoft PACS program (Metasoft Bilgisayar Bilgi İşlem Hizmetleri San. Tic. Ltd. Şti. Eskişehir, Turkey) and a 15.5-inch Sony VAIO monitor with 1920x1200 pixels.

Embeddedness Classification of Third Molars

In our study, panoramic and tomographic images of 388 impacted third molars of 205 patients with bone or gingival retention and failure to reach occlusion were analyzed. The angle of the longitudinal axis with the occlusal plane, its position relative to the occlusal level of the neighboring tooth, and, for mandibular teeth, its position with the anterior edge of the ramus were taken into account when classifying the teeth.

Third molars were classified as impacted according to their functional position in the occlusal plane.

Examination of Panoramic Radiography

According to the Winter classification, teeth with an occlusal plane angle of 10° to -10° with the vertical axis of the tooth were classified as vertical, 10° to 80° as mesioangular, -10° to -80° as distoangular, and 80° to 100° as distoangular. In addition, teeth with a superposed apex and crown that could not be identified on the panoramic image were classified as buccoangular and lingoangular by tomographic evaluation.

According to the Pell-Gregory classification, the occlusal plane of the third molar was classified as position A if it reached the occlusal plane of the adjacent second molar, position B if it was between the occlusal and cervical levels of the second molar, and position C if it was below the cervical level.

Figure 1. Panoramic view of impacted tooth. Examination of CBCT image;

In the Pell-Gregory classification, an examination of mandibular impacted third molars is based on the relationship with the anterior edge of the ramus. In this classification, if the distance between the distal border of the second molar tooth and the anterior edge of the ramus is wider than the mesiodistal dimension of the third molar tooth, it is called Class I; if it is narrower, it is called Class II; and if the entire third molar tooth is embedded in the ramus, it is called Class III.

After the classification was completed, the contact surfaces of the impacted third molars and the adjacent second molars were examined using the magnification feature in the panoramic imaging program. Radiolucency and loss of lamina dura, clearly seen in the root of the second molar, were considered external root resorption. The level of resorption at the distal root of the second molar was divided into two groups: "absent" and "present". Disruption of enamel continuity in the crown region of the second molar or the presence of radiolucency reaching the dentin was evaluated in favor of distal caries. The presence of caries in the distal second molar was classified as "absent" or "present".

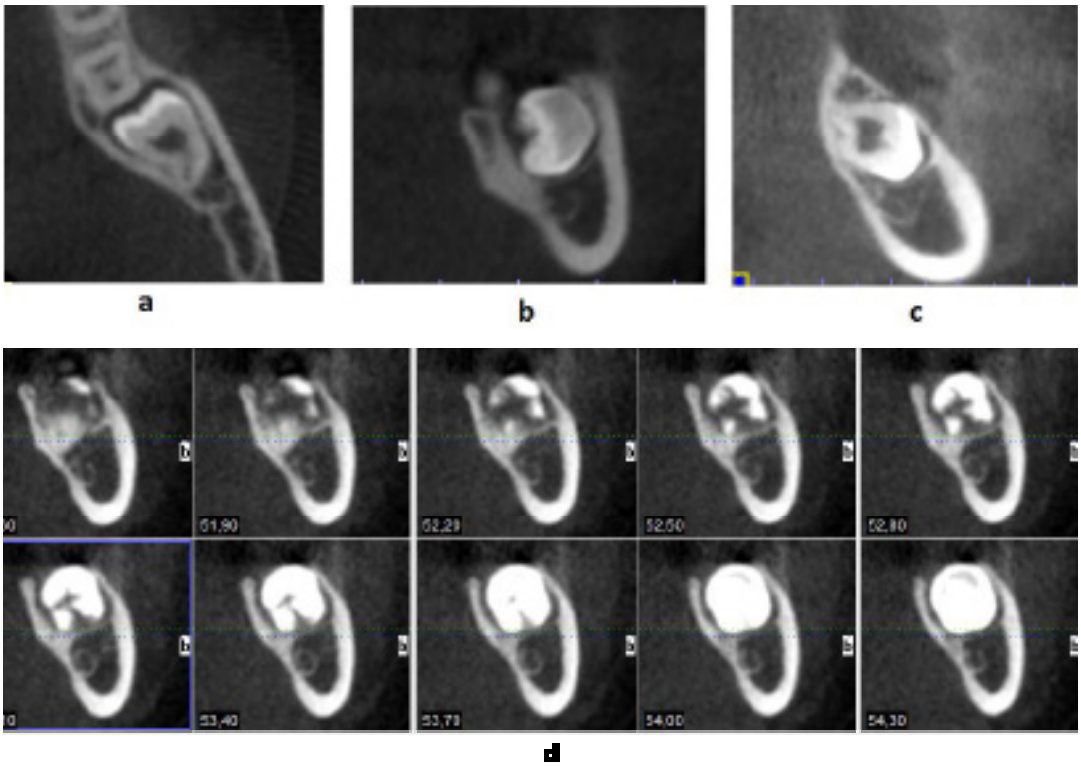

Figure 2. CBCT cross-sectional images of impacted maxillary third molar; a: coronal section, b: sagittal section, c: axial section, d: view in vertical sections.

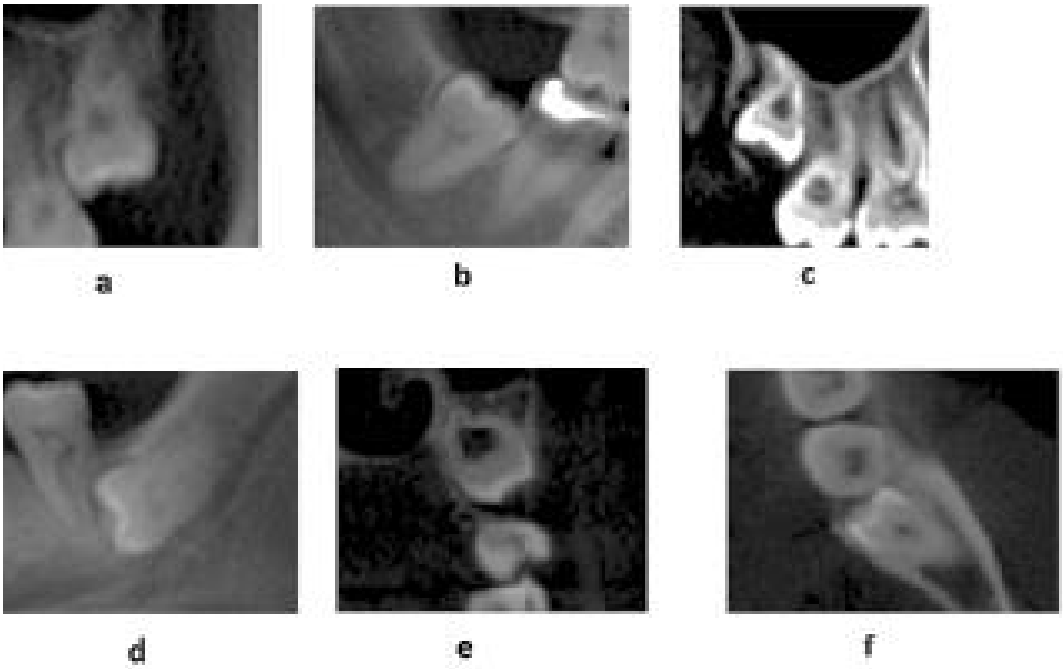

Figure 3. a: vertical **b:** mesioangular **c:** distoangular **d:** horizontal **e:** buccoangular **f:** lingoangular

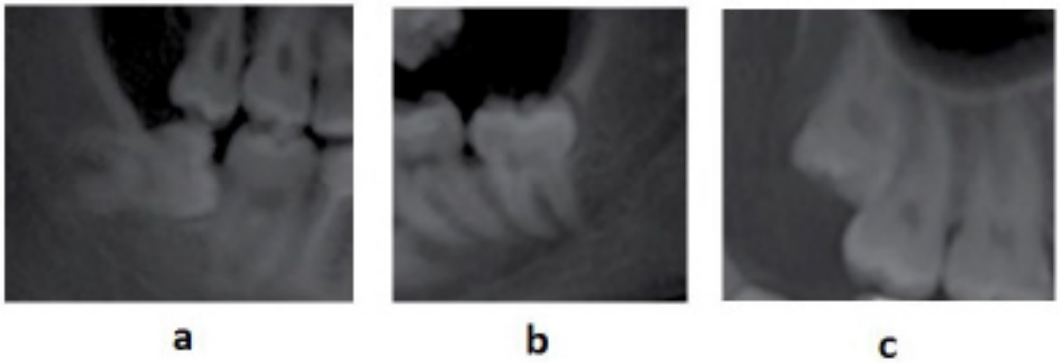

Figure 4. a: Position a, b: Position b, c: Position c

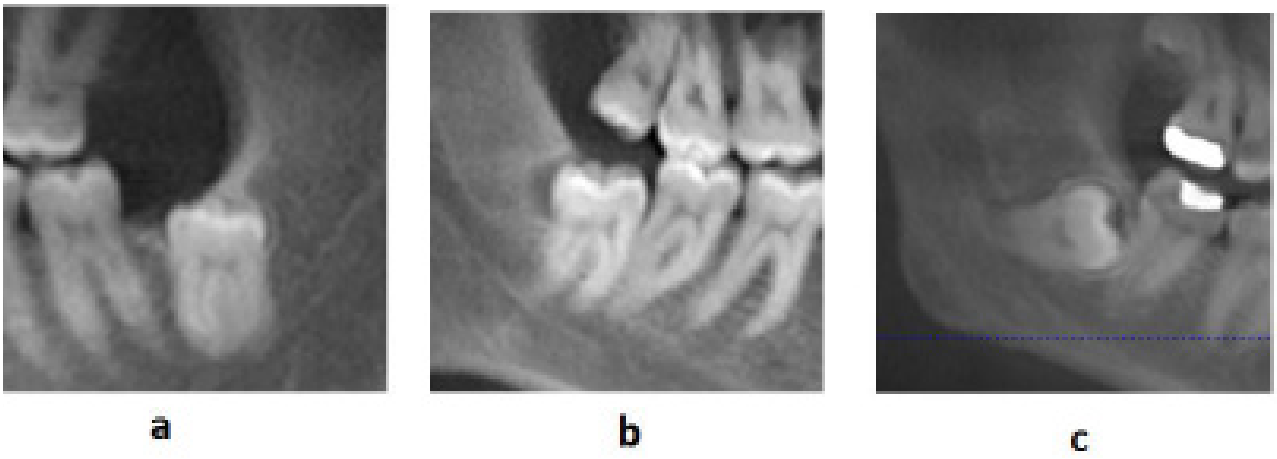

Figure 5. a: Class I **b:** Class II **c:** Class III

Figure 6. External root resorption (panoramic radiographic image)

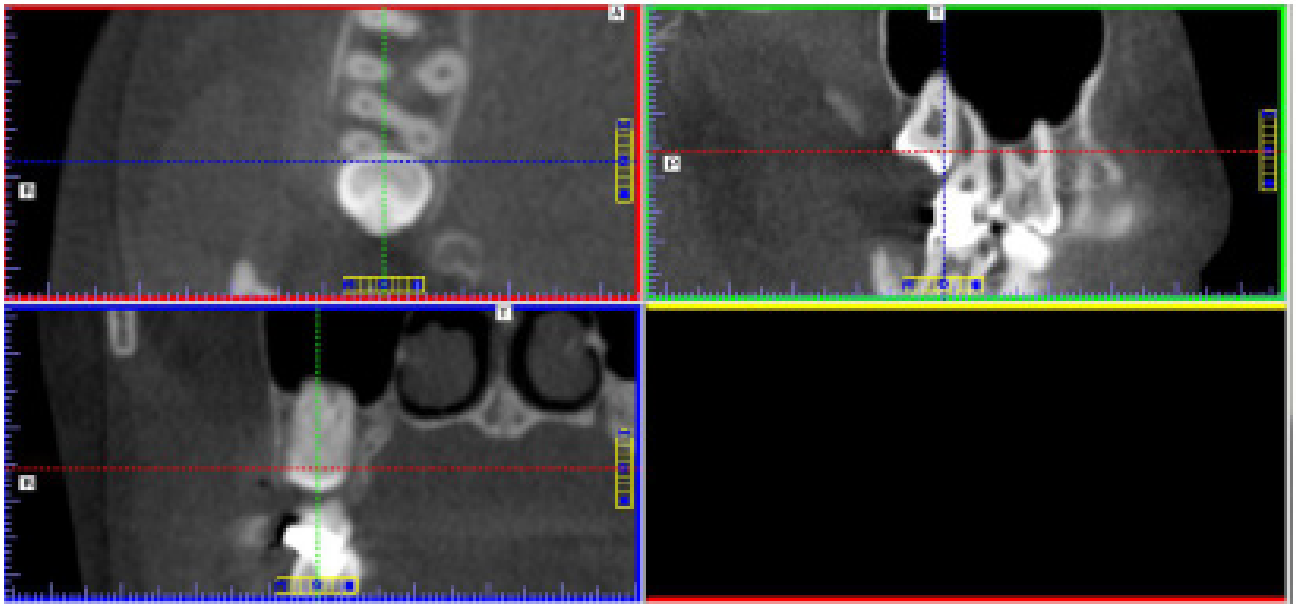

Figure 7. Examination of external root resorption on CBCT image (coronal, sagittal and axial sections)

In addition, 3 mm below the enamel cementum level of the second molar tooth was considered normal bone level, and the results obtained from the most apical measurement of bone destruction were evaluated as marginal bone loss values.[28]

When examining the CBCT images, the external root resorption, distal caries, and bone loss were evaluated using the magnification feature in axial, coronal, and sagittal images. To measure marginal bone loss, the observers noted the measurement from 3 mm below the enamel cementum border of the second molar to the usual bone border as marginal bone destruction, as examined in the case studies.

Figure 8. Presence of distal caries in tooth 47, absence of distal caries in tooth 37

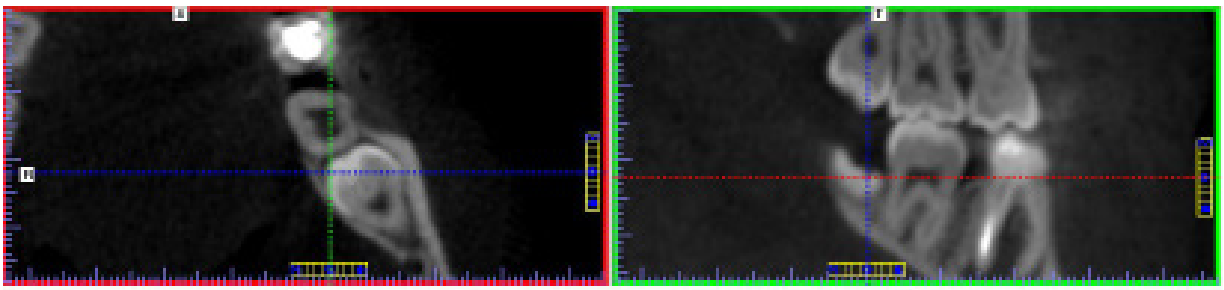

Figure 9. CBCT image of distal absence of caries in tooth 37 (axial and sagittal sections)

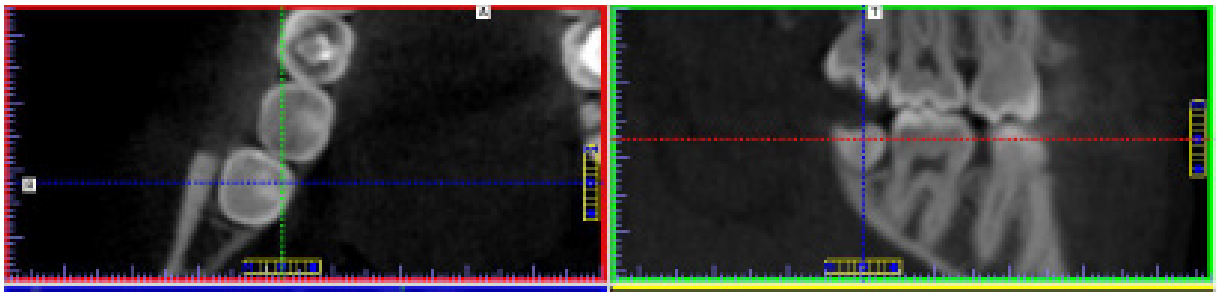

Figure 10. CBCT image of distal caries in tooth 47 (axial and sagittal sections)

Figure 11. Panoramic image of a patient scheduled for marginal bone destruction measurement

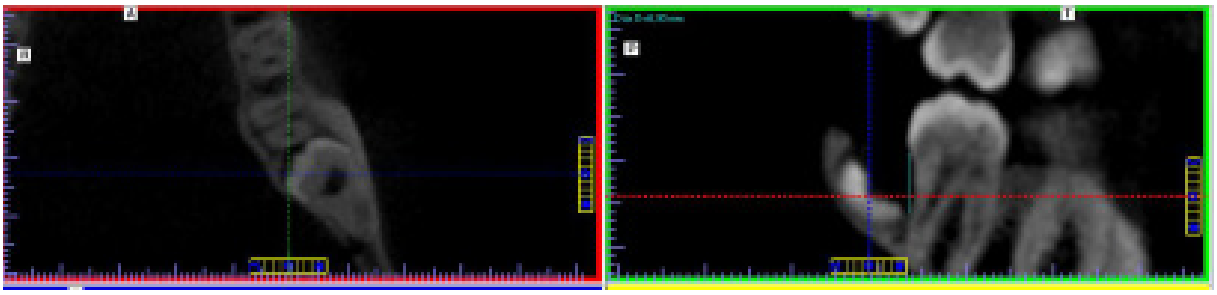

Figure 12. Measurement of 6.30 mm of marginal bone loss caused by tooth 38 on CBCT image (axial and sagittal sections)

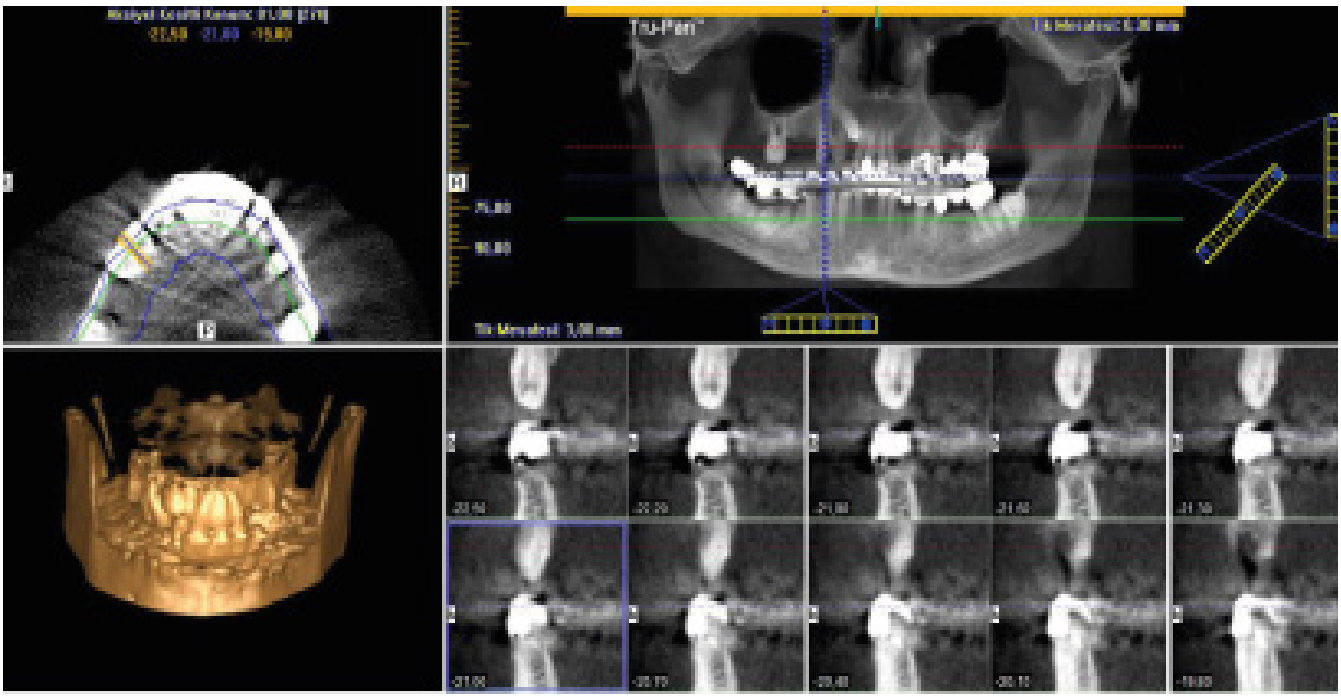

Figure 13. Metal artifact from metal restorations most commonly observed on CBCT image

RESULTS

In the study, panoramic and CBCT images of 205 patients, 114 female (55.6%) and 91 male (44.4%), were evaluated (**Table 1**), 388 impacted third molars were identified (**Table 2**), and the teeth were classified in 3 different ways according to the adjacent tooth in terms of depth, according to the ramus (Pell and Gregory classification), and according to the angle made by the long axis (Winter classification).

When the gender distribution of the patients included in the study was analyzed, 55.6% were female and 44.4% were male.

When the numbers of impacted teeth were analyzed, 15.2% had tooth number 18, 20.1% had tooth number 28, 35.6% had tooth number 38, and 29.1% had tooth number 48.

When the positions of the teeth according to the occlusal distance of the adjacent teeth were examined, 2.6% were inverted, 13.7% were in position A, 34.3% were in position B, and 49.5% were in position C. When the distance of the mandibular teeth to the anterior edge of the ramus was analyzed, it was determined that the most common position was Class II with 47.7%, and the distance between the distal border of the second molar tooth and the anterior edge of the ramus was narrower than the mesiodistal distance of the third molar tooth. In addition, 28.1% of the teeth were vertical, 18% horizontal, 10.6% distoangular, 29.4% mesioangular, 7.2% buccoangular, and 4.1% lingoangular.

There was no statistically significant relationship between the genders in terms of distal caries, marginal bone loss, and external root resorption on cone beam computed tomography and panoramic radiography (p>0.05).

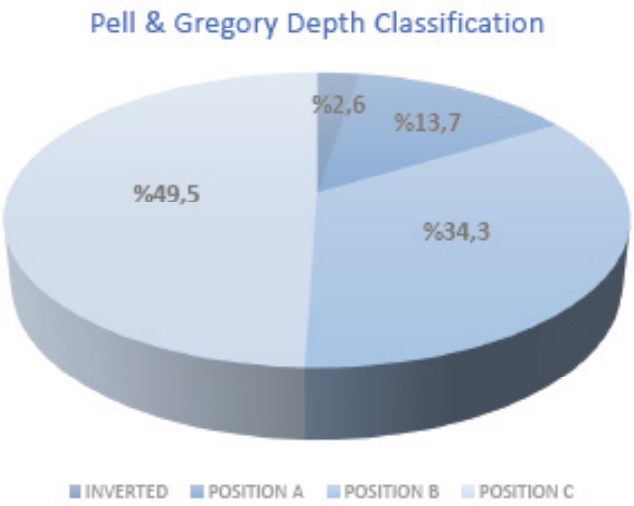

Graph 1: Pell & Gregory depth classification distribution of the teeth included in the study

There is a statistically significant relationship between the distal caries formation groups in the CBCT and panoramic radiography examinations, according to the Pell & Gregory classification of the distance to the anterior edge of the ramus of the teeth included in the study (p<0.05). In the panoramic radiography examination, it was determined that 34.7% (n=87) Class II teeth formed distal caries. In addition, distal caries was observed in 92.6% of the teeth in the Class II group. However, according to tomographic examination, 37.5% (n=94) of the impacted teeth with distal caries were in Class II, and this group was the most common. In the CBCT evaluation, 89.5% of the impacted teeth in the Class II group were found to have distal caries. The teeth in Class III also had the highest rate of caries-free teeth. In the panoramic examination, 92.1% had no caries, while in the CBCT examination, 84.2% had no caries (**Table 1**).

There was a statistically significant correlation between the presence of marginal bone loss groups in panoramic radiography and CBCT examination according to the distance to the anterior face of the ramus (p<0.05). If the distance between the anterior edge of the ramus and the distal border of the second molar is greater than the size of the impacted tooth (Class I), the rate of marginal bone loss (CBCT evaluation was 2.4% and panoramic evaluation was 1.2%) is low. Of the 185 impacted teeth in Class II, 74.6% in panoramic evaluation and 74.6% in CBCT evaluation caused marginal bone loss. In 38 Class III teeth, 71.1% in panoramic evaluation and 78.9% in CBCT evaluation showed marginal bone loss. There was no statistically significant correlation between the external root resorption formation groups in panoramic and CBCT image examinations according to the distance to the anterior ramus of the mandible (p>0.05) (**Table 1**).

There is a statistically significant relationship between the distal caries formation groups in panoramic and CBCT examinations, according to the Pell & Gregory positions of the patients included in the study (p<0.05). Position B (13.4%; n=52) was the most caries-producing position in the panoramic radiography evaluation, while position B (12.4%; n=48) was the most distal caries-producing position in the CBCT evaluation. The distal caries-free rate was in favor of position C in both panoramic (41.8%) and CBCT (39%) evaluations (**Table 1**).

There was a statistically significant relationship between the external root resorption groups according to depth level (p<0.05). In panoramic evaluation, the incidence of external root resorption was higher in position C (24.2%) than in position A (3.4%) and position B (13.1%). In the CBCT evaluation, it was determined that position C (31.7%) showed more external root resorption than position A (4.4%) and position B (15.2%) (**Table 1**).

In the evaluation of CBCT and panoramic images, it was determined that there was a statistically significant difference between the rates of marginal bone loss according to the depth level (p<0.05). In panoramic radiographs, marginal bone loss was most frequently observed in position C with a rate of 36.1%, whereas in CBCT evaluation, the rate increased to 43.3%, with the highest rate in position C. However, the position that caused the least marginal bone loss was position A (5.2%) in the panoramic evaluation, while the result in the CBCT examination showed position A (4.9%) (**Table 1**).

Table 1. Comparison of the relationship between pathologies and positions in panoramic and CBCT results

		PANORAMIC						CBCT					
		Distal Caries		External Root Resorption		Marginal Bone Loss		Distal Caries		External Root Resorption		Marginal Bone Loss	
		Present	Absent	Present	Absent	Present	Absent	Present	Absent	Present	Absent	Present	Absent
		n(%)	n(%)	n(%)	n(%)	n(%)	n(%)	n(%)	n(%)	n(%)	n(%)	n(%)	n(%)
Angulation	Vertical	7.2	20.9	1.0	1.5	18.0	10.1	10.8	17.3	12.4	15.7	20.6	7.5
	Horizontal	6.4	11.6	10.3	7.7	14.7	3.4	5.4	12.6	11.1	7.0	15.7	2.3
	Mesioa.	10.6	18.8	10.3	19.1	24.2	5.2	10.8	18.6	13.4	16	26.3	3.1
	Distoa.	14.6	9	4.9	5.7	6.4	4.1	2.3	8.2	6.7	3.9	9.3	1.3
	Buccoa.	0	7.2	5.2	2.1	4.9	2.3	0	7.2	5.9	1.3	5.9	1.3
	Lingoa.	1.5	2.6	1.5	2.6	2.3	2.3	1.8	2.3	1.8	2.3	2.6	1.6
	Inverted	0	2.6	1	1.5	0.3	2.3	0	17.3	0.8	1.8	0.3	2.3
	p	0.000*		0.000*		0.000*		0.000*		0.001*		0.000*	
Depth	Position A	6.2	7.5	3.4	10.3	8.5	5.2	8.5	5.2	4.4	9.3	8.8	4.9
	Position B	13.4	20.9	13.1	21.1	26	8.2	12.4	21.9	15.2	19.2	28.4	5.9
	Position C	7.7	41.8	24.2	25.3	36.1	13.4	10.3	39.2	31.7	17.8	43.3	6.2
	Inverted	0	2.6	1.0	1.5	0.3	2.3	0	2.6	0.8	1.8	0.3	2.3
	p	0.000*		0.011*		0.000*		0.000*		0.000*		0.000*	
Ramus classification	Class I	1.6	5.6	2.4	4.8	6.0	1.2	2.0	5.2	3.2	4.0	4.8	2.4
	Class II	34.7	39	23.1	50.6	55.0	18.7	37.5	36.3	29.9	43.8	58.6	15.1
	Class III	1.2	13.9	6.8	8.4	10.8	4.4	2.4	12.7	17.3	8.0	12.0	3.2
	Inverted	4.0	0	1.6	2.4	0.4	3.6	4.0	4.0	1.2	2.8	0.4	3.6
	p	0.000*		0.441		0.000*		0.000*		0.749		0.000*	

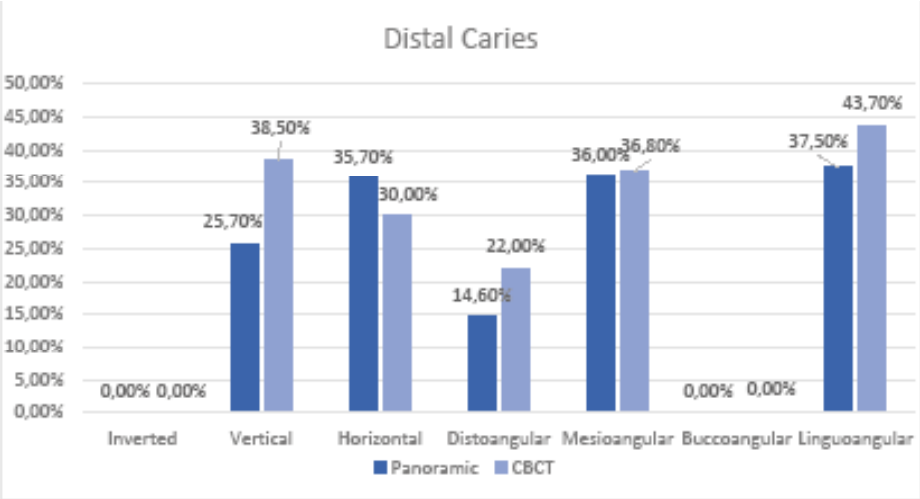

Graph 2: Percentage graph of distal caries formation according to angulation groups

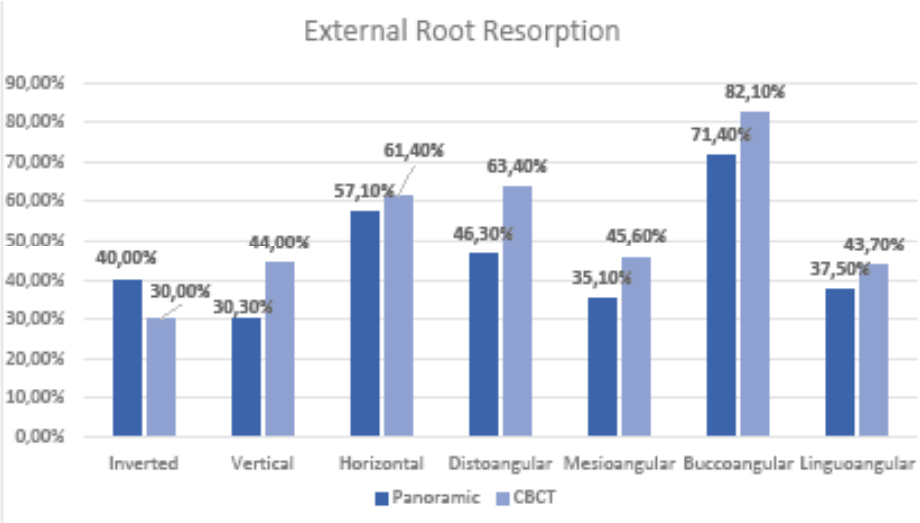

Graph 3: Percentage plot of external root resorption formation according to angulation groups

There is a statistically significant relationship between the distal caries groups in the CBCT and panoramic evaluation according to angulations ($p<0.05$). In panoramic evaluation, the most common angulations were mesioangular (10.6%), vertical (7.2%), and horizontal (6.4%). In CBCT evaluation, mesioangular and vertical (10.8%) caused the highest rate of distal caries formation, followed by horizontal (5.4%) (Table 1).

There was a statistically significant difference in external root resorption according to angulation in CBCT and panoramic examination in impacted 3rd molars (p:0.001 for CBCT and p:0.000 for panoramic; $p<0.05$). In the CBCT evaluation, the rate of external root resorption in the mesioangular position (13.4%) was higher than the vertical (12.4%) and horizontal (11.1%) positions. In panoramic evaluation, the ratio of mesioangular and horizontal (10.3%) was the same and higher than vertical (8.5%).

In impacted third molars, a statistically significant difference was found between the rates of marginal bone loss according to angulation in CBCT and panoramic evaluation (p:0.000; $p<0.05$). In the general population, it was observed that the most marginal bone loss occurred in the mesioangular position. While 24.2% bone loss was found in the mesioangular position and 18% in the vertical position in the panoramic evaluation, 26.3% for the mesioangular position and 20.6% for the vertical position in the CBCT evaluation (**Table 1**). In panoramic examination, the rate of marginal bone loss was higher in the mesioangular (82.5%), horizontal (81.4%), and buccoangular (67.9%) positions compared to the inverted (10%) position. Similarly, the rate of marginal bone loss was higher in the mesioangular (89.5%), horizontal (87.1%), and distoangular (87.8%) positions compared to the inverted (10%) and lingoangular (62.5%) positions (**Table 4**).

There is a statistically significant correlation between the rates of distal caries and external root resorption in CBCT and panoramic radiographs ($p<0.05$). In the maxilla and mandible, the rates for all three pathologies were lower in panoramic radiography than in CBCT. The caries incidence rate in the adjacent molars of the mandible was 37.8% in panoramic radiography and 42.2% in CBCT. Similarly, for the upper jaw, the rate of distal caries was 8% in panoramic radiography, while this rate increased to 10.9% in CBCT. Similarly, for the mandible, 34.3% of external root resorption was seen in panoramic radiography, while 41.4% was found in CBCT. While 55.5% external root resorption was detected in the adjacent tooth of the upper jaw in the panoramic examination, it was found to be 71.3% in the CBCT examination.

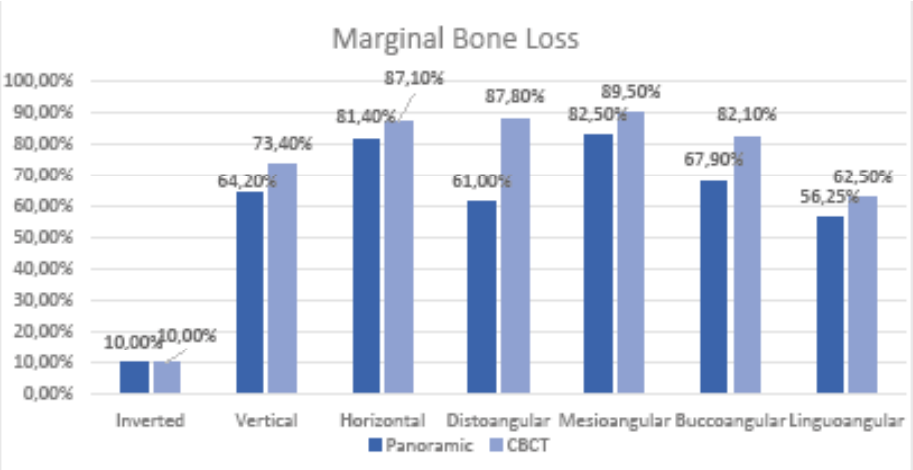

Graph 4: Percentage graph of marginal bone loss formation according to angulation groups

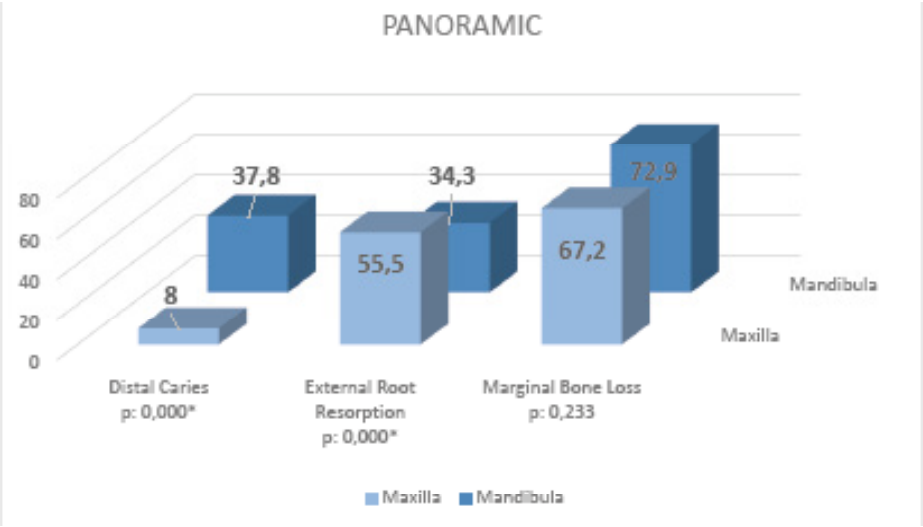

Graph 5: Panoramic evaluation of upper and lower impacted molar pathologies.

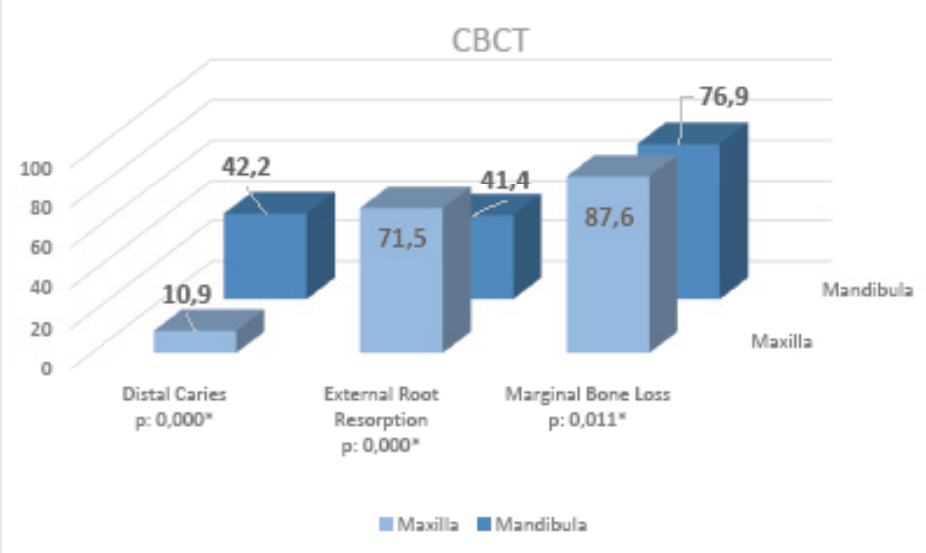

Graph 6: CBCT evaluation of upper and lower impacted molar pathologies.

There was no statistically significant difference in the rate of marginal bone loss between the jaws in the panoramic evaluation (p>0.05). However, a statistically significant difference was found between the rates of marginal bone loss in the CBCT evaluation (p: 0.011*; p<0.05), and it was concluded that 87.6% of marginal bone loss was seen in the upper jaw and 76.9% in the lower jaw.

Table 2. Comparison of CBCT and panoramic radiography for the presence of distal caries in patients

Distal Caries 0 1			Panoramic		Total
CBCT	**0**	n	239	28	267
		%	89.5%	10.5%	100.0%
		% Dental class	84.8%	26.4%	68.8%
		% Total	61.6%	7.2%	68.8%
	1	n	43	78	121
		%	35.5%	64.5%	100.0%
		% Dental class	15.2%	73.6%	31.2%
		% Total	11.1%	20.1%	31.2%
X2: 122.173			**p: 0.000***		

There was a statistically significant difference between the CBCT and panoramic evaluation groups for distal caries in the second molar (p<0.05). Distal caries was observed in 11.1% of the patients who did not have distal caries in the panoramic evaluation, but distal caries was observed in the CBCT evaluation. The proportion of images with distal caries in both CBCT and panoramic evaluation was 20.1%. Similarly, in 7.2% of the examinations, distal caries was observed in the panoramic evaluation but not in the CBCT evaluation.

Table 3. Comparison of CBCT and panoramic radiography for the presence of external root resorption in patients

External Root Resorption 0 1			Panoramic		Total
CBCT	0	n	153	33	186
		%	82.3%	17.7%	100.0%
		% Dental class	67.7%	20.4%	47.9%
		% Total	39.4%	8.5%	47.9%
	1	n	73	129	202
		%	36.1%	63.9%	100.0%
		% Dental class	32.3%	79.6%	52.1%
		% Total	18.8%	33.2%	52.1%
X2: 84.692			p: 0.000*		

There is a statistically significant relationship between the panoramic and CBCT evaluation groups in terms of external root resorption (p<0.05). The proportion of images in which external root resorption was not found in panoramic evaluation but was found in the CBCT evaluation was 18.8%. The proportion of images with external root resorption in both CBCT and panoramic evaluation is 33.2%. Similarly, in 8.5% of the examinations, external root resorption was observed in the panoramic evaluation but not in the CBCT evaluation.

Table 4: Comparison of CBCT and panoramic radiography for the presence of marginal bone loss in patients

Marginal Bone Loss 0 1			Panoramic		Total
CBCT	**0**	n	50	25	75
		%	66.7%	33.3%	100.0%
		% Dental class	44.2%	9.1%	19.3%
		% Total	12.9%	6.4%	19.3%
	1	n	63	250	313
		%	20.1%	79.9%	100.0%
		% Dental class	55.8%	90.9%	80.7%
		% Total	16.2%	64.4%	80.7%
X2: 63.483			**p: 0.000***		

There was a statistically significant correlation between the panoramic and CBCT evaluation groups in terms of marginal bone loss between the two teeth (p<0.05). 64.4% of the radiographs showed marginal bone loss in both panoramic and CBCT evaluations, while 16.2% showed marginal bone loss in CBCT images that was not observed in panoramic radiography. In 9.1% of the radiographs in which bone loss was observed on panoramic evaluation, no bone destruction was observed on CBCT evaluation.

Table 5. Statistical evaluation of marginal bone loss measurement in patients

		Mean ± Standard Deviation	Minimum	Maximum	Test Value	p
Gender	Female	3.47±2.02	0.00	10.88	2.754	0.005*
	Male	2.92±1.46	0.00	6.70		
Jaw	Maxilla	3.24±1.61	0.00	10.88	0.671	0.503
	Mandibula	3.11±1.84	0.00	10.03		
Dental Class	18	1.45±0.20	0.00	6.66	1.265	0.286
	28	1.70±0.20	0.40	10.88		
	38	1.69±0.16	0.00	7.38		
	48	2.01±0.21	0.00	10.03		
Position	Inverted	1.89±3.27	0.00	5.66	1.652	0.177
	Position a	3.50±2.09	1.00	10.88		
	Position b	2.96±1.71	0.00	10.03		
	Position c	3.25±1.67	0.00	9.42		
Class	Inverted 1	1.89±3.27	0.00	5.66	2.696	0.047* (1>2.3)
	Position I 2	4.35±2.59	0.00	10.03		
	Position II 3	3.00±1.61	0.00	6.72		
	Position III 4	3.25±2.28	0.00	9.42		

*p<0.05

The marginal bone loss in the adjacent tooth of the impacted third molars examined in the study was measured in mm on CBCT radiographs. While there was no statistically significant difference in bone loss measurements according to the jaw and depth classification (p>0.05), there was a statistically significant difference according to gender and ramus classification (p<0.05). It is seen that the bone loss mm values of females are higher than those of males. The bone loss mm values of Class I teeth were higher than those of Class II and Class III teeth.

DATA ANALYSIS

The data obtained in the study were analyzed using the SPSS 25.0 program. Descriptive statistical methods (number, percentage, minimum-maximum values, mean, and standard deviation) were used to evaluate the data.

The normal distribution of the data depends on the skewness and kurtosis values being between ±1.5. For the comparison of quantitative data in normally distributed data, an independent sample t test was used for the difference between two independent groups, a one-way analysis of variance was used for the difference between more than two independent groups, and a Bonferroni pairwise comparison test was used to determine which group the difference originated from. The relationship between categorical variables was investigated with the chi-square test. The significance level was accepted as 95%.

DISCUSSION

Impacted third molars are a common oral health problem that causes problems such as pain, swelling, and infection in patients and may cause pathologies such as caries, external root resorption, or bone destruction, which are often unrecognized by the individual.[5] Long-term retention of these teeth in the jaws is known to be a risk factor for related pathologies such as caries, periodontal diseases, cysts, and tumors.[6]

Discussion of the Material Method

In addition to intraoral examinations, radiologic examinations are also needed for a detailed examination of the complications caused by impacted third molars. Two-dimensional imaging modalities such as periapical, occlusal, and panoramic radiographs are the standard diagnostic imaging modalities for the evaluation of teeth and surrounding lesions.[7] Although it has a lower radiation dose compared to CBCT, it has disadvantages such as lack of buccolingual evaluation, failure to show initial lesions, superposition of surrounding tissues, magnifications, distortion of images, and perspective problems.[8,7] In the images obtained with CBCT, tissues are examined in coronal, sagittal, and axial sections without superposition.[4]

Matzen et al.[9] evaluated the pathologic findings related to mandibular third molars, resorption, and marginal bone loss in second molars comparatively on PR and CBCT images in their study with four observers. They examined variables such as angulation type, contact point with the second molar, resorption and marginal bone loss on the distal surface of the tooth, and the presence of periodontal space in the third molars.

Yeşiltepe et al.[10] examined 188 maxillaries impacted third molars in 121 patients aged 18 years and older on CBCT images. Embeddedness, angulation type, root development, follicle width, relationship with the maxillary sinus, marginal bone loss distal to the adjacent maxillary second molar, presence of caries, and level of distal root resorption were evaluated by two observers.

Kang et al.[3] classified five hundred mandibular third molars without root resorption, large cavities, and cystic lesions in CBCT images of 469 patients according to their degree of impactedness and angulation and retrospectively analyzed findings such as the presence of distal caries in the second molars, the cementoenamel junction distance between the second and third molars, and the presence of pericoronitis in the third molars according to age and gender.

Our study is similar to the studies of Matzen et al.[9] and Yeşiltepe et al.[10] in terms of the images used and the parameters analyzed. One of the differences of our study is that Matzen et al.[9] additionally examined the increased periodontal space in the third molar in their evaluation of panoramic and CBCT images. In addition to these parameters, we also examined the presence of distal caries. The differences in our study are that both maxillary and mandibular teeth were evaluated, and the relationship of maxillary teeth to the sinus was not evaluated. However, we classified the impacted teeth in our study in the same way as Kang et al.[3]

Discussion of Radiographic Evaluations

a. Evaluation of the relationship with the anterior edge of the ramus

Patel et al.[11] compared panoramic radiography and CBCT findings for the relationship between impacted mandibular third molar root and inferior alveolar nerve canal and found a prevalence of 51% Class I, 36.5% Class II, and 11.5% Class III impacted third molars.

Garcia et al.[12] found a prevalence of 32% in Class I, 28% in Class II, and 39% in Class III in their study, in which they examined 166 teeth to evaluate the difficulty of surgical extraction according to the Pell & Gregory classification.

Göksu et al.[13] reported that 46.2% were in Class II, 27.1% in Class III, and 26.7% in Class I positions in their study.

In our study, we observed the mandibular third molars more or less in Class II (73.7%), Class III, and Class I positions, respectively. Although studies on the evaluation of impacted mandibular third molars according to ramus distance have reported different results, the majority of them show that the mandibular third molars are usually impacted in Class II and Class III positions. In our study, it was observed that the lower impacted third molar was frequently found in Class II and Class III positions. These results, which are consistent with the literature, support the idea that space limitation is highly associated with impacted teeth. The Class I position was found to be the least common position, with a rate of 7.2%.

b. Evaluation of the type of angulation

Jung and Cho[16] evaluated CBCT data and found that the most common angulation type of maxillary third molars was vertical (59.0%), followed by buccoangular (18.2%) and mesioangular (13.2%).

Göksu et al.[13] retrospectively analyzed the positions of impacted mandibular third molars from a demographic point of view on panoramic X-ray images and reported that vertical angulation was the most common according to the Winter classification.

Patel et al.[11] reported the most common angulation type as vertical in their study, in which they compared panoramic and CBCT findings for the relationship between the root and inferior alveolar nerve canal of impacted third molars.

Peker et al.[14] reported that the most common angulation type was mesioangular in their study, in which they examined the relationship with the inferior alveolar canal in the preoperative examination of mandibular impacted third molars using panoramic X-rays and CBCT.

Syed et al.[4] reported that the most common angulation type was mesioangular (60.4%) and then horizontal (24.4%) in their study, in which they examined 979 panoramic radiographs from Saudi people and found that 39% of impacted third molars caused distal caries in the second molars.

It is difficult to compare studies on impacted third molars due to different classification systems (according to angulation, degree of impactedness, and ramus). In most of the studies, classifications were made with two-dimensional imaging. However, in our study, the images were evaluated with both two- and three-dimensional graphics, and it was found that the most common angulation type was mesioangular, followed by vertical and horizontal types, respectively. The least common angulation type, lingoangular position, was seen in 4.1% of the teeth.

In our study, in agreement with Peker et al.[14] and in contrast to Jung and Cho[16] and Göksu et al.[13], the most common angulation type was the mesioangular type. These proportional differences in the literature are thought to be due to the study method and the genetic differences of the patient group included in the study. In addition, in our study, the presence of distal caries (panoramic 10.8%; CBCT 10.6%) was found most frequently in the teeth in the mesioangular angulation, in accordance with the study of Syed et al.

c. Evaluation of the depth relationship according to the occlusal table

When the literature is examined, Hugoson and Kugelberg[17], who investigated the classification of impacted teeth according to the adjacent second molar, reported that position A was more common in the lower jaw, while Quek et al.[18] reported that position B was common in 85% of impacted teeth in the lower jaw. Yuasa et al.[19] found similar results, with a rate of 42.1% for position B and 29.6% for position C. In the teeth included in our study, position C was observed most frequently, with a rate of 49.5% according to the Archer classification, followed by position B with 34.3% and position A with 13.7%. We attribute the high rate of position C in our study, which is different from the literature, to the fact that the studies were conducted with individuals belonging to different races and that genetic differences were determinative for these reasons.

d. Evaluation of caries distal to the second molar

Dental caries is one of the most common problems seen in panoramic radiographs of second molars adjacent to third molars.[3] Distal surface caries in the second molar is considered a late complication of eruption or impacted third molars.[20] Caries caused by impacted third molars in second molars sometimes require the removal of the third molar and restoration of the caries defect. Furthermore, in some cases where caries lesions are too large to be restored, the involved second molars are extracted, resulting in a significant loss of masticatory function. Early detection and evaluation of the caries' risk associated with second molars may help in the prevention of distal caries in second molars.[3]

Özeç et al.[21] reported that the prevalence of distal second molar caries associated with partially or completely impacted third molars ranged from 20% to 47% in their study based on panoramic X-rays. McArdle et al.[22] reported a 15% incidence of distal caries in their study, in which they calculated the costs associated with distal caries of second molars associated with impacted mandibular third molars with a mesioangular angle. Kang et al.[3], using cone beam computed tomography to diagnose caries, found that the rate of an affected caries on the distal surface of the adjacent mandibular second molars caused by mandibular third molars was as high as 52%.

Xiang et al.[23] analyzed distal caries on the distal surface of the distal surface of the mandibular second molars induced by impacted mandibular third molars using panoramic X-rays and found that the prevalence of distal caries was 37.6% and the caries rate in position B was higher than in position A. In our study, the prevalence of distal caries in position B was 13.4% on panoramic radiography and 12.4% on CBCT.

Ye et al.[24] reported the presence of distal caries in mandibular second molars with a prevalence of 18.75% in a study conducted to evaluate the relationship between impacted mandibular third molars and pathologies caused by impacted third molars. 72.22% of the mandibularly impacted third molars were observed in position A, 20.83% in position B, and 6.94% in position C. They also reported that the frequency of distal caries in mandibular second molars was highest in mesioangular impacted teeth in position A. We detected distal caries most frequently in position B, with a rate of 13.4% in panoramic and 12.4% in CBCT. The results of our study are consistent with those of Xiang et al.[23], but not with those of Ye et al.[24]

AlHobail et al.[25] analyzed panoramic and bitewing radiographic images for the presence of caries on the distal surface of second molars associated with third molars in Saudi patients and found a prevalence of 48.6%. They identified mesioangular angulation as a risk factor for distal caries. They also reported distoangular impaction as a protective factor for dental caries.

In our study, distal caries due to impacted third molars were detected in 27.3% of panoramic radiographs and 31.7% of CBCT. This result is generally compatible with the results reported in the literature.[3,21-25] This proportional difference between the studies may be due to the number of patients/teeth, oral hygiene status/adherence to the selected population, and inclusion criteria.

In our study, distal caries was found to be 8% panoramic and 10.9% CBCT in the maxilla, while it was 37.8% panoramic and 42.2% CBCT in the mandible, and a significant difference was found between the jaws in terms of caries incidence rates. In this study, the incidence of caries may have been different in the CBCT assessment, possibly because some surface caries was not easily identified on panoramic radiographs. This suggests that CBCT has greater sensitivity and accuracy than panoramic and intraoral radiographs in the diagnosis of caries adjacent to the distal aspect of the second molar.

In routine treatment procedures, panoramic radiography is preferred to CBCT due to reservations about cost, equipment, and radiation dose. However, in prosthodontic, orthodontic, and surgical treatments and periodontal procedures where the second molars are to be retained in the mouth (use as an abutment for prosthodontic restorations and orthodontic treatments, restoration of lost occlusion, fixation in cases of trauma, support in cases where there are many missing teeth in the anterior region, splinting, etc.), the retention of the second molars gains value. In cases where prognosis is important, it is absolutely necessary to keep the second molars in the mouth. In terms of its superiority in detecting initial pathologies, CBCT can be used by the physician in such cases, considering the profit-loss ratio.

In our study, CBCT evaluation found that mesioangular impacted third molars caused distal caries with a rate of 36.8% in the mesioangular, 30% in the horizontal, and 38.5% in the vertical. These rates were found to be 36% in the mesioangular, 35.7% in the horizontal, and 25.7% in the vertical in the panoramic evaluation. Our study is consistent with the studies of Ye et al.[24], AlHobail et al.[25], and McArdle et al.[22]

The highest caries rate (37.5%) in the neighboring second molars in CBCT images occurred in the third molar Class II position. This may be due to the fact that the impacted third molar creates a gap with the adjacent second molar, which leads to a higher food accumulation effect that is not conducive to cleaning and caries formation on the surface of the nearest second molar.

There is a lack of comparative panoramic and CBCT studies investigating distal caries associated with third molars in the literature. Our study aims to shed light on this gap in the literature. In the 388 teeth examined in this study, distal caries was observed in 78 teeth in common on CBCT and panoramic X-rays. While distal caries was observed in a total of 121 teeth in the CBCT evaluation, it was determined in 106 teeth in the panoramic evaluation. The reason for the 28 teeth (7.2%) with distal caries on panoramic X-rays but not on CBCT was thought to be cervical burnout or the optical illusion effect, which is among the panoramic image errors. In addition, the rate of teeth with distal caries on CBCT was 31.2%, while this rate was 11.1% on panoramic. This suggests that approximately two out of three caries cannot be observed on panoramic X-rays and that the physician may miss two out of every three caries. Further studies are needed to obtain more detailed information on this subject.

e. Evaluation of marginal bone defect on the distal surface of second molars

Bağış et al.[26], in their study comparing intraoral radiography and CBCT in the detection of periodontal defects, reported that CBCT achieved the highest sensitivity and diagnostic success in the detection of many periodontal pathologies. They also reported that this success was higher in posterior teeth than in anterior teeth.

Matzen et al.[27] measured the marginal bone loss on the distal surface of the mandibular second molars associated with impacted third molars on CBCT images and reported a marginal bone loss rate of approximately 49%. They identified mesioangular and horizontally positioned mandibular third molars as risk factors. They also reported the agreement between panoramic and CBCT as 66-85% for marginal bone loss and 54-74% for external root resorption.

Dias et al.[28] compared marginal bone loss in second molars due to impacted mandibular third molars between panoramic images and CBCT and found an incidence of 62.9% in panoramic images and 80% in CBCT images. Approximately 29% of the teeth with no bone loss on panoramic images showed bone loss on CBCT scans. In general, they reported that panoramic X-rays underestimate the severity of bone destruction compared to CBCT.

Hermann et al.[29] found the incidence of marginal bone loss in the distal part of maxillary second molars to be 84.9% on CBCT scans and 81.6% on panoramic scans in a comparative study of upper jaw teeth using panoramic and CBCT images. They found that although some of the resorption seen on CBCT was not seen on panoramic X-rays, it could be seen to a large extent.

Moreira-Souza et al.[30], in a review of 539 articles, reported that the prevalence of marginal bone loss ranged from 21.9% to 62.9% on panoramic and 21.6% to 80% on CBCT. They reported that the consistency between panoramic and CBCT ranged between 66% and 85%.

This study is consistent with the studies of Dias et al., Hermann et al., and Moreira-Souza et al. The incidence of marginal bone loss was 80.7% on CBCT and 64.4% on panoramic X-ray. In addition, it was determined that teeth in the mesioangular position caused 82.5% marginal bone loss in panoramic and 89.5% in CBCT. In horizontal angulation, 81.4% marginal bone loss was observed in panoramic and 87.1% in CBCT. This result confirms mesioangular and horizontal angulation as risk factors.

In our study, it was observed that the greater the depth of the impacted tooth in the mandible, the more marginal bone loss was observed. In panoramic evaluation, the incidence of bone destruction was 8.5% in position A, 26% in position B, and 36.1% in position C. In the CBCT evaluation, the incidence of bone destruction was 8.8% in position A, 28.4% in position B, and 43.3% in position C.

It seems reasonable to evaluate marginal bone loss by CBCT, as it is more reliable in making the diagnosis. Therefore, CBCT is indicated when a treatment decision is to be made for second molar resorption.

f. Evaluation of external root resorption in second molars

When the impacted teeth are close to the roots of the neighboring teeth, they may initiate the process of external root resorption through mechanical and chemical stimuli on the neighboring tooth root.

In their study, Yamaoka et al.[31] reported that external root resorption due to third molars was more common in males and associated this with the effect of sex hormones. In our study, no significant difference was found between external root resorption and gender.

Tunç et al.[32] reported a higher incidence of external root resorption in CBCT studies compared to studies using panoramic radiography. Since CBCT provides multi-planar reconstruction images, external root resorption of the second molars caused by the third molars can be evaluated more accurately than two-dimensional imaging techniques.

Vaz de Souza et al.[33] compared CBCT and periapical radiographs in the detection of external root resorption in mandibular teeth and found that CBCT was significantly better in the detection of external root resorption. In our study comparing panoramic and CBCT images, we found that the frequency of external root resorption was higher on CBCT (52.1%) than on panoramic radiographs (33.2%). In 10.3% of patients who did not have external root resorption on panoramic radiographs, we observed external root resorption on CBCT images. In the presence of mesioangularly impacted mandibular third molars, the incidence of external root resorption in the second molars was 35.1% on panoramic and 45.6% on CBCT. In addition, the incidence of external root resorption in teeth in position C was 24.2% on panoramic and 31.7% on CBCT. The fact that the contact area between the second and third molars is wider in this type of angulation

and depth leads to more transmission of mechanical pressure to the tooth roots due to eruption movement that may cause resorption.

Li et al.[32] found the prevalence of external root resorption to be 32.6% in the maxilla and 52.9% in the mandible in a retrospective study of CBCT images. Mesioangular and position C third molars were identified as risk factors. In our study, the prevalence was 55.5% for maxilla and 34.3% for mandible on panoramic, and 71.5% for maxilla and 41.4% for mandible on CBCT. These proportional differences in the literature are thought to be due to differences in the study method and the patient group included in the study.

Wang et al.[34] evaluated the incidence of external root resorption in second molars with mesioangular and horizontally impacted mandibular third molars using CBCT images from patients in China and reported that patients with 29.8% impacted in position A had the highest incidence of external root resorption in second molars, followed by position C (24.5%) and B (16.1%). Similarly, a gradual increase in the incidence of external root resorption was observed from position A to C in both CBCT and panoramic evaluation. In our study, in accordance with the literature, mandibularly impacted third molars in position C had a higher incidence of external root resorption than those in positions A and B (34-35). This may be due to the fact that the point of contact with the neighboring tooth as a result of the eruption movement coincides with the root surface of the second molar tooth and induces external root resorption.

In our study, it was also found that the incidence of external root resorption was higher in the maxilla (71.5%) than in the mandible (41.4%) on CBCT and in the maxilla (55.5%) than in the mandible (34.3%) on panoramic. Similar results were reported by Oenning et al.[36], Li et al.[35], and Tunç et al.[32] who reported that 33.6% of impacted 3rd molars caused external root resorption, and this rate was 22% and 11.6% in the maxilla and mandible, respectively.

Caries, external root resorption, and marginal bone destruction in the distal part of the second molars are among the complications associated with impacted third molars, and it has been reported that CBCT is a more detailed method than two-dimensional imaging for detecting such complications before intervention in impacted third molars.[9,10,29,30] Although there are publications on CBCT, comparative studies of three-dimensional and two-dimensional imaging techniques in diagnosis are lacking in the literature.[29,30] In this study, the relationship between second molars and impacted third molars was demonstrated on CBCT and panoramic X-rays.

Detection and evaluation of pathologies such as external root resorption, marginal bone loss, and caries are difficult on panoramic X-rays due to the superposition of anatomical structures and adjacent teeth. In a study by Hermann et al.[29], it was reported that the detection of external root resorption was not possible with panoramic compared to CBCT, while the detection of marginal bone loss was partially possible. In addition, it has been demonstrated in the literature that 2D imaging methods such as panoramic, periapical, and bitewing are not as successful as CBCT in detecting caries lesions in the distal part of the second molar.[21,37]

Three-dimensional information is usually required to evaluate root resorption and root surface morphology, especially in the early stages.[38] While external root resorption was detected on CBCT in 202 second molar teeth adjacent to 388 impacted third molars, no resorption was detected on a panoramic radiograph in 73 of these teeth, and no resorption was seen on CBCT in 33 of 162 teeth with external root resorption on a panoramic radiograph. The two imaging methods showed a common finding of external root resorption in only 129 teeth (33.2%). Similarly, the presence of external root resorption in both imaging techniques was consistent with the studies of Alqerban et al.[39] (4.9%) and Oenning et al.[36] (4.3%). The underlying reason for this result is thought to be the fact that CBCT provides three-dimensional images, and that superposition is not seen in films viewed in the axial and sagittal planes.

CONCLUSION

CBCT is a more reliable method than panoramic radiography in the evaluation of distal caries, marginal bone loss, and external root resorption pathologies. Impacted third molars close to occlusion but not reached (position B) were identified as a risk factor for distal caries. Physicians should inform individuals about this area, which is risky in terms of soft tissue retention and food accumulation in terms of oral hygiene.

The prognosis of asymptomatic third molars located in the bone may be underestimated by clinicians. However, in our study, it was determined to be a risk factor for external root resorption and marginal bone loss. Therefore, prophylactic extraction may be considered. Class 2 position was determined as a risk factor for all three pathologies (distal caries, external root resorption, and marginal bone loss). In third molars that are close to eruption, the physician should carefully examine the second molar and adjacent structures.

External root resorption is most commonly observed in the horizontal and mesioangular positions, while marginal bone loss is most commonly observed in the mesioangular position. Therefore, the patient should continue to be followed up for external root resorption and marginal bone loss in teeth that continue to erupt and are close to the second molars.

ETHICAL DECLARATIONS

Ethics Committee Approval: The ethics committee approval required for the study, which was conducted at Dicle University Faculty of Dentistry, Department of Restorative Dental Treatment, was evaluated at the Dicle University Faculty of Dentistry Ethics Committee meeting dated 28.04.2021, numbered 4, and the decision was taken with the meeting decision with protocol number 2021/27.

Informed Consent: All patients signed and free and informed consent form.

Referee Evaluation Process: Externally peer-reviewed.

Conflict of Interest Statement: The authors have no conflicts of interest to declare.

Financial Disclosure: The authors declared that this study has received no financial support.

Author Contributions: All of the authors declare that they have all participated in the design, execution, and analysis of the paper, and that they have approved the final version.

REFERENCES

1. Alling CC, Helfrick JF, Alling RD. Impacted Teeth. W.B. Saunders Company, Philadelphia 1993:196.
2. Purfasar F, Salemi F, Dalband M, Khamverdi Z. Prevalence of impacted teeth and their radiographic signs in panoramic radiographs of patients referred to Hamadan dental school in 2009. *Avicenna J Dent Res.* 2011;3(1):25-31.
3. Kang F, Huang C, Sah M, Jiang B. Effect of Eruption Status of the Mandibular Third Molar on Distal Caries in the Adjacent Second Molar. *J Oral Maxillofac Surg* 2016;74(4):684-692.
4. Loubele M, Bogaerts R, Van Dijck E, Pauwels R, Vanheusden S, Suetens P, et al. Comparison between effective radiation dose of CBCT and MSCT scanners for dentomaxillofacial applications. Eur J Radiol 2009; 71(3):461-468.
5. Song F LD, Glenny A, Sheldon T. Prophylactic removal of impacted third molars: an assessment of published reviews. *Brit Dent J.* 1997;182(9):339-346.
6. National Institute for Clinical Excellence and Guidance on the Extraction of Wisdom Teeth . London, UK : The British Institute of Radiology. 2000.
7. Alqerban A, Jacobs R, Souza P, Willems G. In-vitro comparison of two cone-beam computed tomography systems and panoramic imaging for detecting simulated canine impaction induced external root resorption in maxillary lateral incisors. *Am J Orthod Dentofacial Orthop.* 2009;136: 764e1-764e11
8. Kaczor-Urbanowicz K, Zadurska M, Czochrowska E. Impacted teeth: an interdisciplinary perspective. *Adv Clin Exp Med.* 2016;25(3):575-585.
9. Matzen L, Schropp L, Spin-Neto R, Wenzel A. Radiographic signs of pathology determining removal of an impacted mandibular third molar assessed in a panoramic image or CBCT. *Dentomaxillofac Radiol.* 2017;46(1):20160330.
10. Yesiltepe S, Kılcı G. Evaluation the relationship between the position and impaction level of the impacted maxillary third molar teeth and marginal bone loss, caries and resorption findings of the second molar teeth with CBCT scans. *Oral Radiol.* 2022;38(2):269-277.
11. Patel PS, Shah JS, Dudhia BB, Butala PB, Jani YV, Macwan RS. Comparison of panoramic radiograph and cone beam computed tomography findings for impacted mandibular third molar root and inferior alveolar nerve canal relation. *Indian J Dent Res.* 2020;31(1):91-102.
12. García AG, Sampedro FG, Rey JG, Vila PG, Martin MS. Pell-Gregory classification is unreliable as a predictor of difficulty in extracting impacted lower third molars. *Br J Oral Maxillofac Surg.* 2000;38(6):585-587.
13. Göksu V,Ersoy H,Eberliköse H, Yücel Z Gömülü Mandibular Üçüncü Molar Diş Pozisyonlarının Demografik Olarak İncelenmesi: Retrospektif Çalışma. *ADO Klinik Bilimler Dergisi (online).* 2021;10(3): 165-171.
14. Peker I, Sarikir C, Alkurt MT. Panoramic radiography and cone-beam computed tomography findings in preoperative examination of impacted mandibular third molars. *BMC Oral Health.* 2014;14(1):71.
15. Syed KB, Alshahrani FS, Alabsi WS, Alqahtani ZA, Hameed MS, Mustafa AB, et al. Prevalence of distal caries in mandibular second molar due to impacted third molar. *JCDR.* 2017;11(3):28-30.
16. Jung YH, Cho BH. Assessment of maxillary third molars with panoramic radiography and cone-beam computed tomography. *Imaging Sci Dent.* 2015;45(4):233-240.
17. Hugoson A, Kugelberg C. The prevalence of third molars in a Swedish population. An epidemiological study. *Community Dent Health* 1988;5(2):121-138.
18. Quek S, Tay C, Tay K, Toh S, Lim K. Pattern of third molar impaction in a Singapore Chinese population: a retrospective radiographic survey. *Int J Oral Maxillofac Surg.* 2003;32(5):548-552.
19. Yuasa H, Kawai T, Sugiura M. Classification of surgical difficulty in extracting impacted third molars. *Br J Oral Maxillofac Surg.* 2002;40(1):26-31.
20. McArdle L, McDonald F, Jones J. Distal cervical caries in the mandibular second molar: an indication for the prophylactic removal of third molar teeth? *Br J Oral Maxillofac Surg.* 2014;52(2):185-189.
21. Ozeç I, Hergüner SS, Taşdemir U, Ezirganli S, Göktolga G. Prevalence and factors affecting the formation of second molar distal caries in a Turkish population. *Int J Oral Maxillofac Surg.* 2009;38(12):1279-1282.
22. McArdle LW, Patel N, Jones J, McDonald F. The mesially impacted mandibular third molar: the incidence and consequences of distal cervical caries in the mandibular second molar. *Surgeon.* 2018;16(2):67-73.
23. Jin X, Zhang X-Z, Jin C-R, Xuan Y-Z. Analysis of factors related to distal proximal caries on the distal surface of the mandibular second molar induced by an impacted mandibular third molar. *Intern J Gen Med.* 2021;14:3659.
24. Ye Z-X, Qian W-H, Wu Y-B, Yang C. Pathologies associated with the mandibular third molar impaction. *Sci. Prog.* 2021; 104(2):368504211013247
25. AlHobail SQ, Baseer MA, Ingle NA, Assery MK, AlSanea JA, AlMugeiren OM. Evaluation distal caries of the second molars in the presence of third molars among Saudi patients. *J Int Soc Prev Community Dent.* 2019;9(5):505-512.
26. Bagis N, Kolsuz ME, Kursun S, Orhan K. Comparison of intraoral radiography and cone-beam computed tomography for the detection of periodontal defects: an in vitro study. *BMC Oral Health.* 2015;15(1):64.
27. Matzen LH, Schropp L, Spin-Neto R, Wenzel A. Use of cone beam computed tomography to assess significant imaging findings related to mandibular third molar impaction. *Oral Surg Oral Med Oral Pathol Oral Radiol.* 2017;124(5):506-516.
28. Dias MJ, Franco A, Junqueira JL, Fayad FT, Pereira PH, Oenning AC. Marginal bone loss in the second molar related to impacted mandibular third molars: comparison between panoramic images and cone beam computed tomography. *Medicina Oral, Patologia Oral Y Cirugia Bucal,* 2020;25(3):395-402.
29. Hermann L, Wenzel A, Schropp L, Matzen LH. Marginal bone loss and resorption of second molars related to maxillary third molars in panoramic images compared with CBCT. *Dentomaxillofacial Radiology.* 2019;48(4):20180313.
30. Moreira-Souza L, Butini Oliveira L, Gaêta-Araujo H, Almeida-Marques M, Asprino L, Oenning AC. Comparison of CBCT and panoramic radiography for the assessment of bone loss and root resorption on the second molar associated with third molar impaction: a systematic review. *Dento Maxillo Facial Radiology,* 2022:51(3), 20210217.
31. Yamaoka M, Furusawa K, Ikeda M, Hasegawa T. Root resorption of mandibular second molar teeth associated with the presence of the third molars. *Aust Dent J.* 1999;44:2112-116.
32. Keskin Tunç S, Koc A. Evaluation of risk factors for external root resorption and dental caries of second molars associated with impacted third molars. *J Oral Maxillofacial Surg.* 2020;78(9):1467-1477.
33. Vaz de Souza D, Schirru E, Mannocci F, Foschi F, Patel S. External cervical resorption: a comparison of the diagnostic efficacy using 2 different cone-beam computed tomographic units and periapical radiographs. *J Endodontics.*2017;43(1):121-125.
34. Wang D, He X, Wang Y, Li Z, Zhu Y, Sun C, et al. External root resorption of the second molar associated with mesially and horizontally impacted mandibular third molar: evidence from cone beam computed tomography. *Clin Oral Invest,* 2017;21(4):1335-1342.
35. Li D, Tao Y, Cui Mea. External root resorption in maxillary and mandibular second molars associated with impacted third molars: a cone-beam computed tomographic study. *Clin Oral Invest* 2019; 23(12):4195-4203.
36. Oenning ACC, Neves FS, Alencar PNB, Prado RF, Groppo FC, Haiter-Neto F. External root resorption of the second molar associated with third molar impaction: comparison of panoramic radiography and cone beam computed tomography. *J Oral Maxillofacial Surg.* 2014;72(8):1444-1455.
37. Şahin O, Çakmak EŞ, Bayrak S, Demiralp KÖ, Ankaral H. External root resorption and caries of mandibular second molar in association with third molar impaction status. *J Dentistry Indonesia.* 2019;26(1):5-9.
38. Strbac GD, Foltin A, Gahleitner A, Bantleon H-P, Watzek G, Bernhart T. The prevalence of root resorption of maxillary incisors caused by impacted maxillary canines *Clin Oral Invest.* 2013;17(2):553-564.
39. Alqerban A, Jacobs R, Fieuws S, Willems G. Comparison of two cone beam computed tomographic systems versus panoramic imaging for localization of impacted maxillary canines and detection of root resorption. *European J Orthodontics.* 2011;33(1):93-102.

Journal of Dental Sciences and Education

Original Article

DOI: 10.51271/JDSE-0014

Evaluation of biocompatibility of four different one-step self-etching adhesives by animal experimental method

Mehmet Salih Aydın[1], Şeyhmus Bakır[2], Elif Pınar Bakır[2]

[1]Diyarbakır Oral and Dental Health Center, Diyarbakır, Turkey
[2] Department of Restorative Dentistry, Faculty of Dentistry, Dicle University, Diyarbakır, Turkey

Cite this article: Aydın MS, Bakır Ş, Bakır E. Investigation of the effects of embedded third molar to the second molar through cbct and panoramic radiography. *J Dent Sci Educ*. 2023;1(3):81-89.

Corresponding Author: Elif Pınar Bakır. elifpinarbakir@gmail.com

Received: 02/09/2023 ◆ **Accepted**: 29/09/2023 ◆ **Published**: 30/09/2023

ABSTRACT

Aim: The success of materials used in dentistry is closely related to their biological safety. In recent years, there has been growing concern about the biocompatibility of self-etch adhesives, which are frequently used in restorative dental treatment. The aim of this study is to compare the biocompatibility of four different single-stage self-etch adhesive materials (prime & bond one select. optibond all-in-one, clearfil universal bond, and single bond universal) with the animal test method and evaluate them histopathologically.

Methods: The experimental materials were polymerized by filling 10 mm-long, 2 mm-diameter polyurethane tubes. For each adhesive, 21 tubes were used. The tubes were placed in the subcutaneous pockets formed by four different incisions in the backs of 21 adult male albino rats. On the 7th, 30th, and 60th days, rats were randomly divided into three groups. At the end of these durations, the tube and the surrounding 2 cm^2 of tissue were excised together. The sections were taken into preparation and stained with hematoxylen and eosin. The severity of inflammation, inflammatory cell count, and fibrous capsule thickness were evaluated histologically by light microscopy.

Results: On the 7th day of samples, lesions due to acute inflammation, edema, and PMNL infiltration were observed. In the 30th-day samples, it was observed that inflammation decreased against all materials and fibrocollagen tissue increased. On the 60th day, granulation and fibrous tissue increased due to regeneration and reparation processes. On the 60th day, the number of inflammatory cells decreased significantly compared to the 7th day. When the fibrous tissue formation was evaluated, it was found that the 7th day score was significantly lower than the 60th day score.

Conclusion: The severity of the inflammatory reaction at the beginning of all materials can be explained by the effects of residual monomer release and surgical trauma.

Keywords: Self-etch adhesive, biocompatibility, animal testing

INTRODUCTION

Adhesive resins, which have been used frequently in restorative dentistry in recent years, have been the materials on which the most biocompatibility research has been conducted because they contain a number of compounds that may cause different biological reactions.[1] Adhesives bond to composite resin as well as enamel and dentin. While bonding to enamel and dentin is explained by micromechanical adhesion, bonding to composite resin can be explained by co-polymerization of the double bonds in the oxygen inhibition layer. This occurs when the resin monomers and the inorganic structure of the tooth are interlocked during polymerization. Micromechanical bonding is a penetration process.[2]

Nowadays, the reclassification of adhesives based on their clinical application procedures and their interactions with dentin has come to the fore.[2,3] According to this classification, adhesive systems are: Etch&Rinse (Acid Wash) Adhesives. Self-etch (Self Acid) Adhesives and Glass Ionomer-Containing Adhesive Systems.[2,4]

Self-etch adhesives can be two- or one-step according to their stages and can be examined in three groups as strong (pH<1), medium (1≤pH≤2), and weak (pH>2) according to their acidizing properties and pH.[5]

The structure of adhesive systems includes acrylic resin monomers, initiators, inhibitors, solvents, and some fillers. Since each component has a special function, it is important to know them in order to determine the current biological risk potential of adhesives.[6] As a result of inadequate polymerization of adhesive materials, some of the monomers in their content may dissolve in saliva. This is known to cause direct biological reactions in cells and tissues.[7,8] In

This work is licensed under a Creative Commons Attribution 4.0 International License.

addition, residual monomers have been reported to cause a delay in odontogenic differentiation and mineralization processes in root cells and pulpal cells.[7] Dental materials should be evaluated for biological risks before clinical use. Biocompatibility is the ability of a material applied to living tissue to remain compatible without causing any change in the surrounding tissues.[9,10] The tests used to investigate the biocompatibility of dental biomaterials are in vitro (primary) tests, in vivo animal experiments (secondary tests), and usage tests.[9]

The main feature of primary tests is the ability to control the interfaces of the biomaterial and the environment of the cells and to measure the cell response precisely and in detail.[9,11-13] In animal experiments, the material to be tested for biocompatibility is implanted into the tissue to evaluate its local toxic effect.[9,11,13] Through animal experiments, it is possible to predict the potential toxic hazards of dental materials before clinical use.[9,11,12,14] The inflammatory tissue response elicited by the implantation of dental materials into the subcutaneous connective tissue of experimental animals is similar to that of exposed pulp connective tissue. The ability to obtain a biological response similar to human tissues has prevented the use of humans as test subjects. Therefore, the subcutaneous implantation test is considered as the most reliable biocompatibility evaluation method in animal experiments.[15]

The aim of this study was to compare the biocompatibility of four different resin-containing single-stage self-etch adhesive materials [Prime&Bond One Select (PB-OS). Optibond All-in-One (OB-AIO). Clearfil Universal Bond (CUB), and Single Bond Universal (SUB)] by animal experiment method and to evaluate them histopathologically.

METHODS

This study was conducted according to the guidelines of ISO 7405 and ISO 10933-6. Dicle University Prof. Dr. Sabahattin Payzın Health Sciences Research and Application Center Animal Experiments Local Ethics Committee (DÜHADEK) approval (Pro. No: 2017/17) was obtained before the study. Four different single-stage self-etch adhesive materials (**Table 1**) were used in the study.

Table 1. Adhesive materials used in the study and their chemical structures

Product trade name	Code	Manufacturer Company	Lot No.
Prime&bond® one select	PB-OS	Dentsply DeTrey Konstanz, Germany	7110158
Optibond® all-in-one	OB-AIO	Kerr Scafati, Italy	67488448
Clearfil® universal bond	CUB	Kuraray Okayama. Japan	1T0014
3M® Single bond universal	SBU	3M ESPE Neuss, Germany	80411B

In this study, 21 male Wistar albino rats weighing 300-400 g were used. Polyurethane tubes of 10 mm in length and 2 mm in diameter were used to prepare the samples. Polyurethane tubes were disinfected with 96% alcohol before application. For each adhesive, 21 polyurethane tubes were used. Dental adhesives were placed in polyurethane tubes under aseptic conditions and polymerized with a light device for 10 seconds on all surfaces of the tubes.

Before the experiment, all rats were anesthetized by placing them in a cotton wool jar of 15% Ether (Sigma-Aldrich, Germany). Intraperitoneal anesthesia of the experimental animals was achieved under aseptic conditions using 75 mg/kg Ketamine hydrochloride (Ketalar® Pfizer, Turkey) and 5 mg/kg Xylazine hydrochloride (Xylazol® Provet, Turkey). Sedation was maintained with 5% Ether throughout the surgical procedure. The incision sites of the animals whose backs were shaved were disinfected with 10% Povidone iodine skin antiseptic. The rats were placed in the prone position, and 4 different incisions with defined borders were made with the help of a scalpel under aseptic conditions: 2 in the back and 2 in the lumbar region (Figure 1). In the incision sites, subcutaneous pockets of 1 cm depth were formed by blunt dissection using dissection scissors. One polyurethane tube containing a different adhesive material was placed in each subcutaneous pocket under aseptic conditions. The prepared incision lines were closed with resorbable 3.0 sutures (Boz, Turkey) and antisepsis were achieved by wiping the wound sites with povidone iodine.

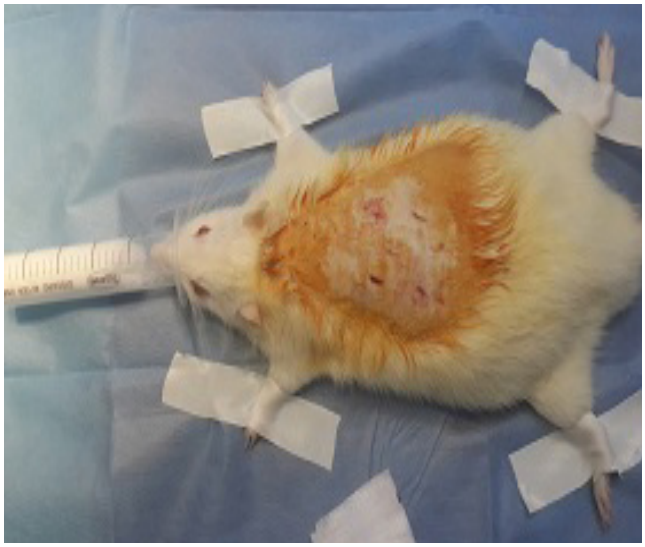

Figure 1. Incision lines on the back and lumbar region of the animals

Twenty-one rats were randomly divided into three equal groups to be examined on days 7, 30, and 60. At the end of the experimental periods, all rats were again anesthetized with ether, and intraperitoneal anesthesia was performed. The dorsal regions of the animals were shaved again, and the area where the samples would be taken was cleaned. Under the cleaned skin, the areas where the implanted samples were located were identified, and the tube and 2 cm^2 of tissue surrounding the tube were cut out together. After the completion of the experimental period, each experimental animal was euthanized by high-dose Thiopental sodium (Pental®İE Ulugay İlaç San, Turkey) anesthesia. Following the experimental periods, the removed specimens were placed in sterile storage containers containing 10% buffered formalin solution and placed in paraffin blocks. Serial 5-µm sections were taken from the prepared paraffin blocks using a microtome and stained with Hematoxylin & Eosin (H&E). Histopathologic examination and evaluation of the sections were performed at Dicle University, Faculty of Veterinary Medicine, Department of Pathology. The preparations were evaluated under a light microscope (Nikon Eclipse E200, Japan) at 40x, 100x, 200x, and 400x magnification and photographed under a light microscope with a digital camera attachment (Nikon Eclipse E400, Japan).

On day 7, samples of the adhesives were evaluated, and lesions due to acute inflammation were observed in the

subcutis and subcutaneous adipose tissue, Edema was seen in the adipose tissue and fibrocollagenous tissue in the periphery of the tube cavity. Extreme hyperemia and severe vasodilation were observed in capillary vessels. There was severe Polymorphonuclear Leukocyte (PMNL) infiltration. There was diffuse leukocyte infiltration consisting mostly of neutrophil granulocytes and lesser amounts of basophils and eosinophils (**Figure 2**).

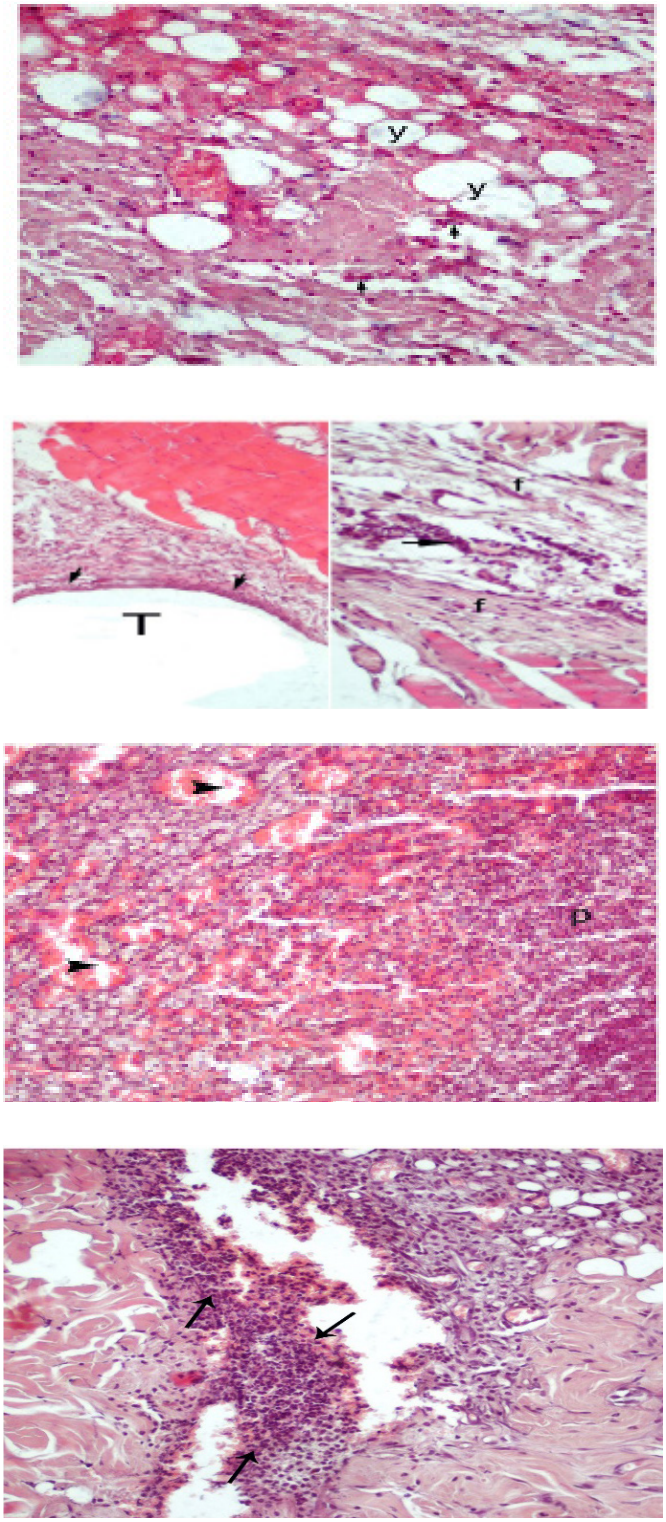

Figure 2. A) PMNL infiltration in day 7 samples of PB-OS (**Arrow;** acute inflammation picture and PMNL infiltration, **Y;** adipose tissue. H&E, 200x magnification). **B)** PMNL infiltration in day 7 samples of OB-AIO material **a:** (**Arrow;** dense PMNL infiltration in the tube mouth, **T;** tube cavity, H&E, 100x magnification). **b:** (**Arrow;** PMNL infiltration, **f;** fibrous tissue, H&E, 200x magnification). **C)** Acute inflammation picture in day 7 samples of CUB material (**Arrow;** vasodilatation due to acute inflammation and severe hyperemia in capillaries, **p;** dense PMNL infiltration, H&E, 200x magnification). **D)** PMNL infiltration in fibrocollagen tissue in day 7 samples of SBU material (**Arrow;** dense PMNL infiltration in fibrocollagen tissue, H&E, 200x magnification).

When the 30th day samples of the adhesives were evaluated, it was observed that the inflammation decreased compared to the 7th day and became subacute; capillary vessel hyperemia and dilatation severity decreased. Vascularization (angio-genesis) was determined due to an increase in fibrocollagen tissue. Diffuse Mononuclear Leukocyte (MNL) infiltration consisting mostly of lymphocytes was observed in fibrocollagen tissue, starting from subcutaneous adipose tissue. Plasma cells, macrophages, and histiocytes, as well as rare PMNLs, were observed (**Figure 3**).

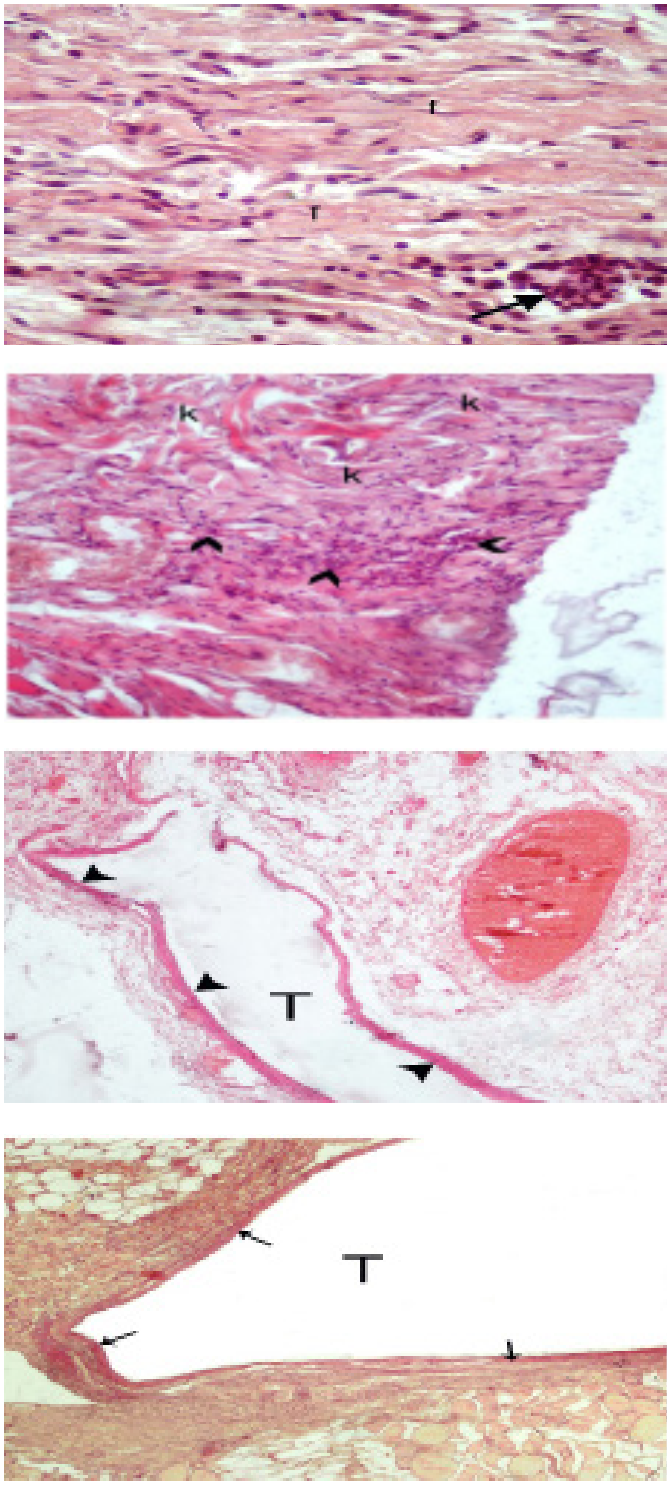

Figure 3. A) Fibrocollagen formation and MNL infiltration in day 30 samples of PB-OS. (**Arrow;** MNL infiltration, **f;** fibrocollagen tissue formation, H&E, 400x magnification). **B)** Fibrocollagen increase and MNL infiltration in day 30 samples of OB-AIO. (**Arrow;** severe MNL infiltration, **k;** increase in fibrocollagen tissue, H&E, 200x magnification). **C)** Fibrocollagen tissue formation in day 30 samples of CUB material. (**Arrow;** lamellar fibrocollagen tissue formation around the tube, **T;** tube cavity, H&E, 100x magnification).
D) Fibrocollagen tissue formation in day 30 samples of SBU material (**Arrow;** severe fibrocollagen tissue formation around the tube in lamellar style, **T;** tube cavity, H&E, 100x magnification)

When the 60th day specimens were evaluated, compared to the 30th day, it was observed that the inflammation decreased and became chronic, and granulation and lamellar fibrous tissue increased due to regeneration and reparation. Very few MNL cells were observed (**Figure 4**).

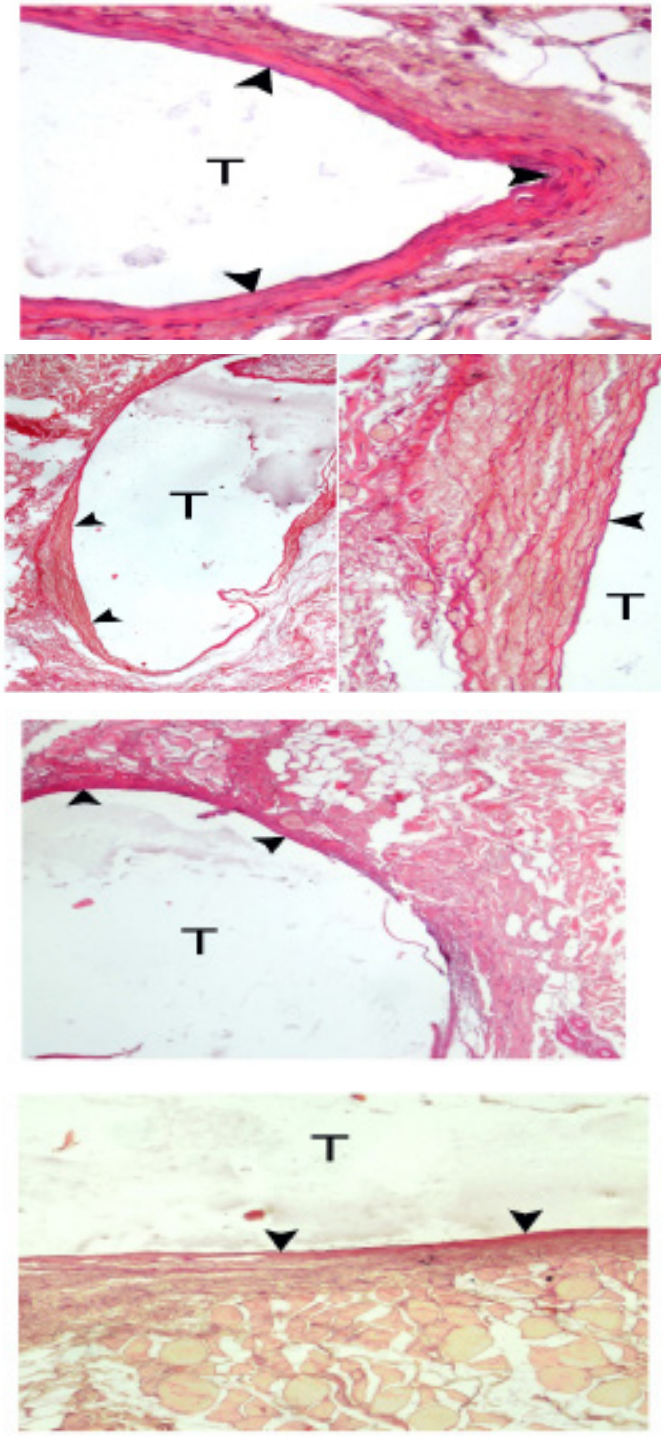

Figure 4: A) Fibrocollagenous tissue formation in day 60 samples of PB-OS. (**Arrow;** dense fibrocollagenous tissue formation around the tube in lamellar fashion, **T;** tube cavity, H&E, 400x magnification. **B)** Severe fibrocollagen formation in day 60 samples of OB-AIO. a: (**Arrow;** severe fibrocollagen tissue formation around the tube in lamellar style, **T;** tube cavity, H&E, 40x magnification) **b:** (**Arrow;** granulation tissue, **T;** tube cavity, H&E, 400x magnification). **C)** Fibrocollagen tissue formation in day 60 specimens of CUB material. (**Arrow;** severe fibrocollagen tissue formation around the tube in lamellar fashion, **T;** tube cavity, H&E, 100x magnification). **D)** Fibrocollagen tissue formation in day 60 samples of SBU material. (**Arrow;** severe fibrocollagen tissue formation around the tube in lamellar fashion, **T;** tube cavity, H&E, 100x magnification).

Statistical Analysis

The SPSS 21.0 computer software program was used for statistical analysis of the results. The findings were shown as "mean ± standard deviation" and conformity to the normal distribution was determined by the Shapiro-Wilk test. Kruskal Wallis-H test was used to analyze the differences between the groups. In cases of significant differences, Post-Hoc multiple comparison test was used to determine the groups with differences. Friedman's Two-Way ANOVA test was used to analyze more than two dependent variables. In cases of significant differences, multiple comparison tests were used. $p<0.05$ was considered statistically significant.

RESULTS

Inflammatory cells around the tube cavity were evaluated under a light microscope in five different fields at 400x magnification. When the 7th day inflammatory cell counts were evaluated, a statistically significant difference was found between the groups ($p<0.05$). The highest cell count was observed in the PB-OS material, while the lowest value was observed in CUB material. In the pairwise comparison of the values between the groups, it was determined that the cell count of the SBU material was significantly lower than that of PB-OS material (**Table 2**).

When the 30th-day inflammatory cell counts were evaluated, a statistically significant difference was found between the groups ($p<0.05$). The highest cell count was observed in the PB-OS material, while the lowest value was observed in OB-AIO material. In the pairwise comparison of the values between the groups, it was determined that the cell counts of OB-AIO and CUB material were significantly lower than the PB-OS material (**Table 3**).

When the 60th-day inflammatory cell counts were evaluated, a statistically significant difference was found between the groups ($p<0.05$). The highest cell count was observed in the PB-OS material, while the lowest value was observed in CUB material. In the pairwise comparison of the values between the groups, it was determined that the cell number of CUB material was significantly lower than that of the PB-OS material (**Table 4**).

Inflammation (PMNL and MNL) and fibrous tissue formation scoring were performed to determine the reaction in the subcutaneous tissue of the rats.

Inflammation scoring criteria were determined as follows: Grade 0 (no reaction); no PMNL and MNL cell infiltration; Grade 1 (mild reaction); PMNL and MNL infiltration involving <20% of all biopsies in Grade 2 (moderate reaction); PMNL and MNL infiltration involving 20-40% of all biopsies in Grade 3 (severe reaction); PMNL and MNL infiltration involving >40% of all biopsies.

The scoring criteria for fibrous tissue formation were determined as follows: Grade 0 (no reaction); normal fibrous tissue morphology; Grade 1 (mild reaction); mild fibrous tissue formation; Grade 2 (moderate reaction); moderate fibrous tissue formation; Grade 3 (severe reaction); severe fibrous tissue formation.

Inflammation and fibrous tissue formation around the tube cavity were evaluated and scored under light microscopy at 40x and 100x magnifications.

Table 2. Difference between day 7 inflammatory cell counts of four different adhesive materials

n		GROUP				Kruskal-Wallis H Test	
		Lowest	Highest	Mean	p	Pairwise comparison	
Inflammatory cell count Day 7	PB-OS (Mean ± SD)	7	168.2	187	180.54±6.09	0.007	SBU/PB-OS
	OB-AIO (Mean ± SD)	7	156.8	178.2	171.09±8.79		
	CUB (Mean ± SD)	7	113.6	183	156.6±26.37		
	SBU (Mean ± SD)	7	138.4	169	157.63±9.75		
	Total	28	113.6	187	166.46±17.42		

Table 3. The difference between the 30th day inflammatory cell counts of four different adhesive materials

n		GROUP				Kruskal-Wallis H Test	
		Lowest	Highest	Mean	p	Pairwise comparison	
Inflammatory cell count Day 30	PB-OS (Mean ± SD)	7	65.2	88.2	72.46±8.19	0.001	OB-AIO/ PB-OS CUB/PB-OS
	OB-AIO (Mean ± SD)	7	40.4	52.2	47.29±4.02		
	CUB (Mean ± SD)	7	44.4	52	48.91±2.42		
	SBU (Mean ± SD)	7	53.6	64.6	57.91±3.82		
	Total	28	40.4	88.2	56.64±11.25		

Table 4. The difference between the inflammatory cell counts of four different adhesive materials at day 60

n		GROUP				Kruskal-Wallis H Test	
		Lowest	Highest	Mean	p	Pairwise comparison	
Inflammatory cell count Day 60	PB-OS (Mean ± SD)	7	7.6	9.2	8.46±0.56	0.002	CUB/PB-OS
	OB-AIO (Mean ± SD)	7	6.8	8.8	7.91±0.75		
	CUB (Mean ± SD)	7	5.8	7.6	6.8±0.57		
	SBU (Mean ± SD)	7	6.6	7.8	7.26±0.5		
	Total	28	5.8	9.2	7.61±0.86		

When the scores of inflammations and fibrous tissue formation were evaluated, no statistically significant difference was observed between the experimental materials ($p>0.05$).

When the inflammation scores of the experimental materials at different time periods were evaluated (**Table 7**. Figure 4), it was determined that the 60th day inflammation score of all materials was significantly lower than the 7th day score ($p<0.05$).

When the fibrous tissue formation scores of the experimental materials at different time periods were evaluated (**Table 7**, **Figure 4)**, it was determined that the 7th day fibrous tissue formation score of PB-OS, OB-AIO, and SBU materials was significantly lower than the 60th day score ($p<0.05$).

When the fibrous tissue formation scores of the CUB material at different time periods were evaluated (**Table 7**. **Figure 4**), it was determined that the fibrous tissue formation score of this material on the 7th day was significantly lower than the 30th and 60th day scores ($p<0.05$).

Table 5. Differences between groups and differences over time

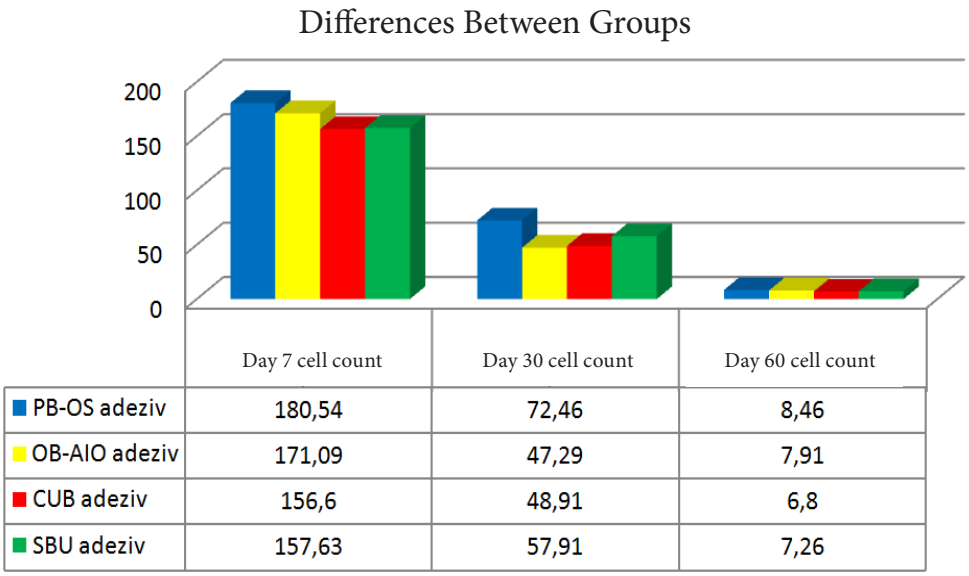

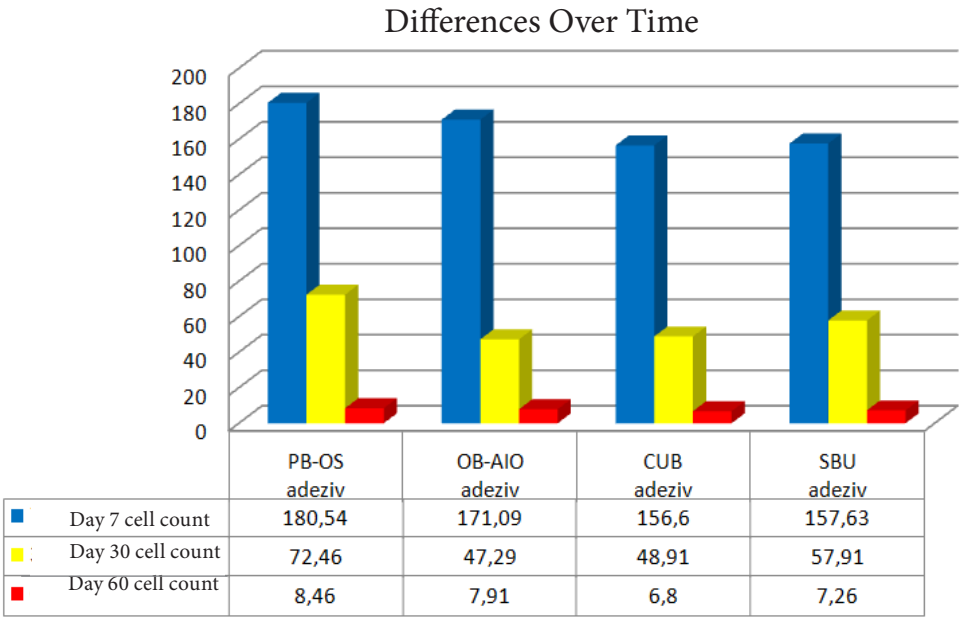

Table 6. Scoring of inflammation and fibrous tissue formation in four different adhesive materials at different time periods

	Day	N	PB-OS				OB-AIO				CUB				SBU			
			G0	G1	G2	G3	G0	G1	G2	G3	G0	G1	G2	G3	G0	G1	G2	G3
Inflammation	7	7	0	0	0	7	0	0	2	5	0	0	1	6	0	0	1	6
	30	7	0	0	5	2	0	0	7	0	0	0	7	0	0	0	6	1
	60	7	0	7	0	0	0	7	0	0	0	7	0	0	0	7	0	0
	7	7	6	1	0	0	7	0	0	0	6	1	0	0	7	0	0	0
Fibrous tissue formation	30	7	0	0	6	1	0	0	5	2	0	0	3	4	0	0	6	1
	60	7	0	0	1	6	0	0	1	6	0	0	1	6	0	0	1	6

Table 7. Findings of inflammation and fibrous tissue formation scores of the materials for different time periods

Friedman's Two-Way Anova Test	Day	PB-OS	Day	OB-AIO	Day	CUB	Day	SBU
Inflammation	7a	0.002	7a	0.002	7a	0.001	7a	0.002
	30		30		30		30	
	60		60		60		60	
Fibrous tissue formation	7a	0.002	7a	0.003	7a	0.006	7a	0.002
	30		30		30b	0.033	30	
	60		60		60		60	

a: Statistical difference between day 7th and 60th p values.
b: Statistical difference between 7th and 30th day p values)

Table 8. Differences between times in terms of inflammation and fibrous tissue formation

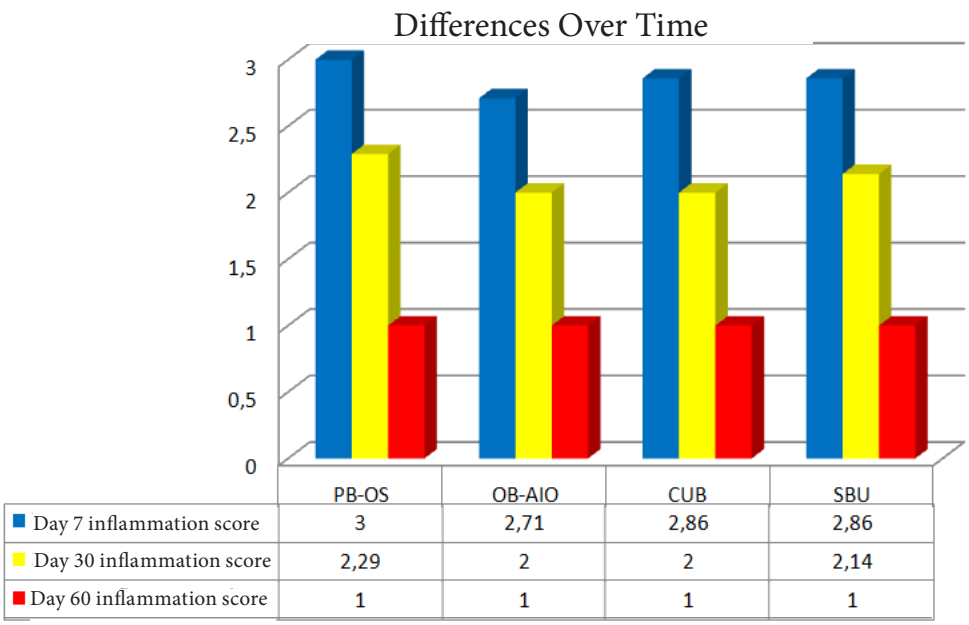

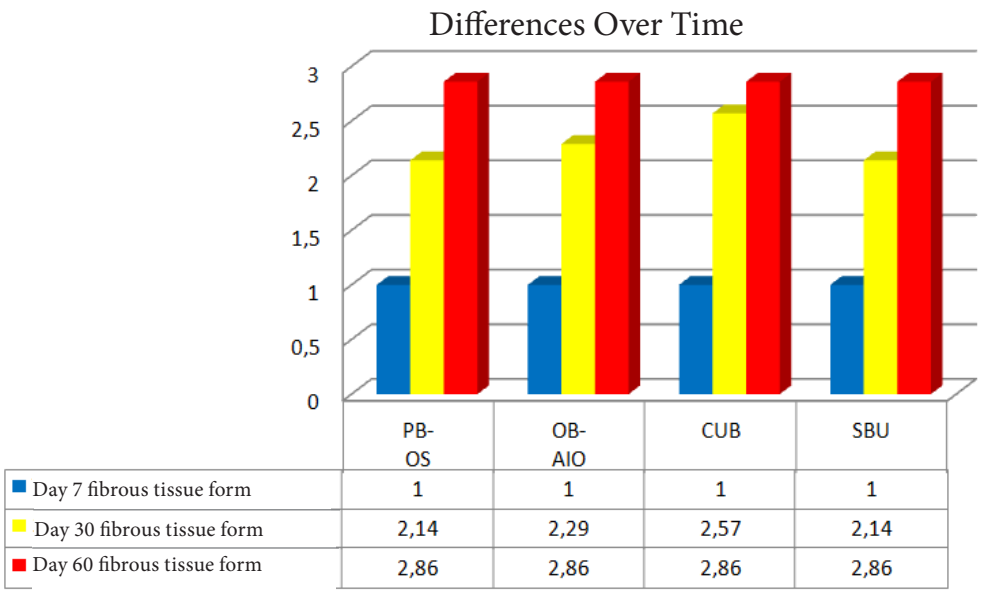

DISCUSSION

The most commonly used resin-containing aesthetic materials in restorative dental treatment is composite resins (16). Resin-containing materials contain various monomers (such as Bis-GMA and UDMA, HEMA and TEGDMA) in different concentrations.[17] It has been reported that the application of resin-containing dental materials in direct contact with the pulp tissue causes pulp inflammation.[18] In the first 24-48 hours following the polymerization of the monomers, the rate of cytotoxicity is at its highest level.[19] This reveals the importance of the remaining dentin thickness

(20). In a study. 34 different components were released from four different resin-containing composite materials.[21]

Today, many materials are offered for clinical use without concern about their biocompatibility.[20] The effects of dental materials on teeth and surrounding tissues, their safety, and their biocompatibility should be investigated before clinical use.[22,23]

In studies, it is mentioned that these components released from adhesive materials into the oral environment cause a number of local and systemic side effects or allergic reactions.[14,24] High doses of TEGDMA, UDMA, Bis-GMA, and Bisphenol-A (BPA) have been found to cause immunosuppression.[25] It is claimed that monomers released from resin materials are tumor initiation risk factors for human salivary glands and also show toxicity in renal cells.[26,27] Al-Hiyasat et al.[28] emphasized a 54.5% decrease in fertility in a study evaluating the effect of BPA on female mouse fertility.

While low concentrations of Bis-GMA induce apoptosis, high concentrations increase cell death with necrosis. Especially after cervical restorations, prolonged contact of Bis-GMA with gingival tissues may cause lichenoid reactions or irritations in the oral mucosa.[29]

In a study by Nowicka et al.[30], the response of the pulp-dentin complex was analyzed after direct pulp capping treatment using self-etch adhesive systems. In most of the specimens, pulpal reaction and lack of dentin bridge formation occurred with tissue disruption. In the teeth in which calcium hydroxide was used, a mild inflammatory response in the pulp with tissue disruption and a high rate of reparative dentin formation were observed. This study is similar to the studies of Koliniotou-Koumpia and Tziafas.[31] and da Silva et al.[32] on dogs.

In an in-vitro study, Süsgün Yıldırım et al.[6] compared the cytotoxicity of five different self-etch adhesives [Prime&Bond One Select (PB-OS), Optibond All-in-One (OB-AIO), G-bond (GB), Clearfil Universal Bond (CUB), Single Bond Universal (SBU)] in cell culture medium. In the SBU, CUB, GB, and OB-AIO groups, zone formation exceeding 1cm around or under the test material was detected. In the PB-OS group, the zone boundaries were close to 1cm. When the effects of the materials incubated at three different time periods on cell proliferation were evaluated; CUB was found to be the most cytotoxic material at the end of the 24-hour incubation period, GB and SBU at the end of the 48-hour incubation period, and OB-AIO at the end of the 72-hour incubation period. It was stated that the cytotoxic effect of all adhesives increased dose-dependently and changed over time.

It is widely believed that these and similar in-vitro studies cannot fully reflect the interactions in living organisms. Indeed, in our study, contrary to these results, we found that PB-OS adhesive material was less biocompatible compared to other adhesives.

In a study by Costa et al.[33] that evaluated the biocompatibility of Clearfill Liner Bond 2, Single Bond, and calcium hydroxide in rats, they used 7, 30, and 60-day periods.[15] evaluated the biocompatibility of three different adhesive materials at 7, 115, and 30-day intervals in a study in rats.[34] used time periods of 15, 30, and 60 days in their similar study on rats. In our study, considering the time-dependent change in the amount of monomer released from the samples, three different time periods (7, 30, and 60 days) were examined and histopathologically evaluated.

In a study by Moysés et al.[15] that evaluated the biocompatibility of three different adhesive materials in rat subcutaneous connective tissue, acute and severe inflammatory responses were detected in all materials except the control group at the end of the 7-day period. On the 15th day, more severe inflammation was observed in Prime&Bond 2.1 and Prime&Bond NT materials compared to Scotchbond MP Primer, and it was determined that the inflammatory process continued on the 30th day. It was concluded that the Scotchbond MP Primer group was more biocompatible than the other two groups.

Costa et al.[33] evaluated the biocompatibility of two different adhesive materials (Clearfil liner bond 2, Single bond) and calcium hydroxide in rat subcutaneous tissues and found an inflammatory response in both adhesive resins at day 7, fibrous capsules at day 30, and connective tissue healing as well as an inflammatory reaction at day 60.

In a similar study, Teixeira et al.[35] evaluated the biocompatibility of three different adhesive materials (Prime&Bond NT, Bond1, and Optibond Solo) with calcium hydroxide and found that intense inflammation was observed at day 15, while a persistent inflammatory reaction persisted at day 60.

Machado et al.[36] examined the biocompatibility of Single Bond, Clearfil SE Bond, and Prime&Bond NT dental adhesives; it was suggested that Prime&Bond NT adhesive material showed less biocompatibility compared to the other two adhesives.

In our study, in which we evaluated the biocompatibility of single-stage self-etch adhesive materials (Prime&bond One Select, Optibond All-in-One, Clearfil Universal Bond, Single Bond Universal), no abscess formation or necrosis was observed in any of the specimens. On day 7, lesions and edema due to acute inflammation were observed against PB-OS and CUB materials. However, there was diffuse PMNL infiltration. Against OB-AIO and SBU materials, PMNL infiltration accompanied by advanced edema was observed in some areas. In the 30th day samples, it was observed that inflammation against all materials decreased, became subacute, and fibrocollagen tissue increased. MNL infiltration, consisting mostly of lymphocytes, was observed. From day 7 onwards, we think that the reason for the rapid decrease in the inflammatory reaction is due to the release of residual monomers and the gradual decrease in the effect of surgical trauma. In the 60th-day specimens, it was observed that the severity of inflammation against all materials decreased further, and granulation and lamellar fibrous tissue increased due to regeneration and reparation processes.

In our study, we determined that the PB-OS adhesive material was less biocompatible compared to the other adhesives. When inflammatory cell counts were evaluated in the 7th and 60th day samples, the highest cell count was observed in the PB-OS material, while the lowest value was observed in CUB material. When the 30th-day inflammatory cell counts were evaluated, the highest cell count was again observed in the PB-OS material, while the lowest value was observed in the OB-AIO material. The number of inflammatory cells in all materials at day 60 significantly decreased compared to day 7. When fibrous tissue formation was evaluated, it was determined that the 7th day score was significantly lower than the 60th day score.

CONCLUSION

In our study, PB-OS adhesive material was found to be less biocompatible than the other adhesives in all groups regardless of time, and at the same time, tissue reaction was controlled over time in all materials. However, biological differences between experimental animals and humans should be taken into consideration when evaluating the results of in vivo studies.

ACKNOWLEDGEMENTS

This study was supported by the Dicle University Scientific Research Projects Coordinatorship (Project No: DİŞ.18.003).

This study is derived from the dissertation entitled "Evaluation of the biocompatibility of four different single-stage self-etch adhesives by animal test method", prepared by Mehmet Salih Aydın, a student of specialization in dentistry, and supervised by Assoc. Prof. Dr. Şeyhmus Bakır.

ETHICAL DECLARATIONS

Ethics Committee Approval: Dicle University Prof. Dr. Sabahattin Payzın Health Sciences Research and Application Center Animal Experiments Local Ethics Committee (DÜHADEK) approval (Pro. No: 2017/17) was obtained before the study.

Informed Consent: Because the study was designed retrospectively, no written informed consent form was obtained from patients.

Referee Evaluation Process: Externally peer-reviewed.

Conflict of Interest Statement: The authors have no conflicts of interest to declare.

Financial Disclosure: The authors declared that this study has received no financial support.

Author Contributions: All of the authors declare that they have all participated in the design, execution, and analysis of the paper, and that they have approved the final version.

REFERENCES

1. Hashimoto M and et al. Fluid movement across the resin-dentin interface during and after bonding. *J Dent Res.* 2004;83(11):843-848.
2. Van Meerbeek B and et al. Adhesion to enamel and dentin:current status and future challenges. *Operative Dentistry.* 2003;28(3):215-235.
3. Batra C, Nagpal R, Tyagi SP, Singh UP, Manuja N. In vitro bonding effectiveness of three different one- step self- etch adhesives with additional enamel etching, *J Investig Clin Dent* 2014;5(3):226-236.
4. Stangel I, Ellis T.H, Sacher E. Adhesion to tooth structure mediated by contemporary bonding systems. *Dent Clin North Am.* 2007;51(3):677-694.
5. Tjäderhane L and et al. Strategies to prevent hydrolytic degradation of the hybrid layer-a review. *Dental Materials.* 2013;29(10):999-1011.
6. Süsgün Yıldırım Z, Bakır Ş, Bakır E, Foto E. Evaluation of Cytotoxicity of Five Different One-step Self-Etching Adhesives in Cell Culture Medium. *Oral Health & Preventive Dentistry.* 2018;16(6):525-532.
7. Atalayın Ç, Tezel H, Ergücü Z. Rezin Esaslı Dental Materyallerin Sitotoksisitesine Genel Bir Bakış. *EÜ Dişhek Fak Derg* 2016;37(2):47-53.
8. Murray PE, Smith AJ, Garcia-Godoy F, Lumley PJ. Comparison of operative procedure variables on pulpal viability in an ex vivo model. *Int Endod J.* 2008;41(5):389-400.
9. Wataha JC. Principles of biocompatibility for dental practioners. *J Prosth Dent* 2001;86:203-209.
10. Williams DF. On the mechanisms of biocompatibility. *Biomaterials* 2008;29:2941-2953.
11. Cao T, Saw TY, Heng BC, Liu H, Yap AUJ, Ng ML. Comparison of different test models for the assesment of cytotoxicity of composite resins. *Journal of Applied Toxicology.* 2005;25:101-108.
12. Moharamzadeh K, Brook IM, Noort RV. Biocompatibility of Resin-based Dental Materials. *Materials* 2009;2(2):514-548.
13. St. John KR. Biocompatibility of dental materials. *Dent Clin North Am* 2007;51(3):747-760.
14. Geurtsen W. Biocompatibility of resin-modified filling materials. *Crit Rev Oral Biol Med.* 2000;11(3):333-355.
15. Moysés MR, Lopes WL, Pereira AAC, Riberio JCR, Dias SC, Pereira LJ. Biocompatibility of the Prime & Bond 2.1, Prime & Bond NT and Scothbond MP Primer adhesive systems. *Braz. J. Oral Sci.* 2006;5(18):1079-1084.
16. Ferracane JL. Resin composite--state of the art. *Dent Mater* 2011;27(1):29-38.
17. Van Landuyt KL and et al. Systematic review of the chemical composition of contemporary dental adhesives. *Biomaterials.* 2007;28(26):3757-3785.
18. Modena KC and et al. Cytotoxicity and biocompatibility of direct and indirect pulp capping materials. *J Appl Oral Sci.* 2009;17(6):544-554.
19. Bagis B, Atilla P, Cakar N, Hasanreisoglu U. Immunohistochemical evaluation of endothelial cell adhesion molecules in human dental pulp:effects of tooth preparation and adhesive application. *Arch. Oral Biol.* 2007;52:705–711.
20. Tadin A, Gavić L, Galić N. Biocompatibility of Dental Adhesives. *Intech Open Science.* 2016; doi.org/10.5772/64943.
21. Spahl W, Budzikiewicz H, Geurtsen W. Determination of leachable components from four commercial dental composites by gas and liquid chromatography/mass spectrometry. *J Dent.* 1998;26(2):137-145.
22. Mjör IA. Practice-based dental research. *J Oral Rehabil.* 2007;34 (12):913-920.
23. Hebling J, Giro EM, Costa CA. Human pulp response after an adhesive system application in deep cavities. *J Dent.* 1999;27(8):557-564.
24. Alanko K, Susitaival P, Jolanki R, Kanerva L. Occupational skin diseases among dental nurses. *Contact Dermatitis.* 2004;50(2):77-82.
25. Wada H, Tarumi H, Imazato S, Narimatsu M, Ebisu S. In vitro estrogenicity of resin composites. *J Dent Res* 2004;83(3):222-226.
26. Goldberg M. In vitro and in vivo studies on the toxicity of dental resin components:a review. *Clin Oral Invest.* 2008;12(1):1-8.
27. Kleinsasser NH, Schmid K, Sassen AW, et al. RFC and genotoxic effects of resin monomers in human salivary gland tissue and lymphocytes as assessed by the single cell microgel electrophoresis. (comet) assay. *Biomaterials.* 2006;27(9):1762-1770.
28. Al-Hiyyasat AS, Darmani H, Elbetieha AM. Leached components from dental composites and their effects on fertility of female mice. *Eur J Oral Sci* 2004;112(3):267-272.
29. Polydorou O, Trittler R, Hellwig E, Kummerer K. Elution of monomers from two conventional dental composite materials. *Dental Materials* 2007;23(12):1535-1541.
30. Nowicka A, Parafiniuk M, Lipski M, Lichota D, Buczkowska-Radlinska J. Pulpo-dentin complex response after direct capping with self-etch adhesive systems. *Folia Histochem Cytobiol.* 2012;50(4):565-573.
31. Koliniotou-Koumpia, E, Tziafas D. Pulpal responses following direct pulp capping of healthy dog teeth with dentine adhesive systems. *J Dent.* 2005;33(8):639-647.
32. da Silva JM and et al. Effectiveness and biological compatibility of different generations of dentin adhesives. *Clin Oral Invest.* 2014;18(2):607-613.
33. Costa CAS, Teixeira HM, Nascimento BL, Hebling J. Biocompatibility of Two Current Adhesive Resins. *Journal of Endodontics.* 2000;26(9):512-516.
34. Omidi S, Javidi M, Zarei M, Mushakhian S, Jafarian A. Subcutaneous connective tissue reaction to a new nano zinc-oxide eugenol sealer in rat model. *Iran. Endod. J.* 2017;12(1):64-69.
35. Teixeira HM, Do Nascimento ABL, Hebling J, Costa CAS. In vivo evaluation of the biocompatibility of three current Bonding agents. *J. Oral Rehabil.* 2006;33(7):542-550.
36. Machado NP, Moysés MR, Pereira AAC, Pereira LJ, Ribeiro JCR, Dias SC. Study of dentinal adhesives compatibility using histological analysis. *Braz. J. Oral Sci.*2007;6(20):1289-1294.

Journal of Dental Sciences and Education

Original Article

DOI: 10.51271/JDSE-0015

In vitro effect of different cleaning procedures of ah plus on microtensile bond strength of immediate or delayed restoration

Türkay Kölüş[1], Özlem Kahveci[2]

[1]Department of Restorative Treatment, Ahmet Keleşoğlu Faculty of Dentistry, Karamanoğlu Mehmetbey University, Karaman, Turkey,
[2]Department of Endodontics, Ahmet Keleşoğlu Faculty of Dentistry, Karamanoğlu Mehmetbey University, Karaman, Turkey

Cite this article: Kölüş T, Kahveci Ö. In vitro effect of different cleaning procedures of ah plus on microtensile bond strength of immediate or delayed restoration. *J Dent Sci Educ*. 2023;1(3):90-94.

Corresponding Author: Türkay Kölüş, turkaykolus@hotmail.com

Received: 01/09/2023 ◆ **Accepted**: 29/09/2023 ◆ **Published**: 30/09/2023

ABSTRACT

Aims: Although immediate restoration is recommended after endodontic treatment, delayed restoration is still required in some cases. Also, the presence of the residual endodontic sealer in the pulp chamber may interfere with the adhesive materials and jeopardize the sealability. The purpose of the study was to determine the effect of different sealer residue cleaning methods on dentin bond strength of immediate or delayed endodontic composite restoration.

Methods: The occlusal surface of seven freshly extracted human molar teeth without caries were prepared to expose the flat dentin surface. Teeth were randomly divided into six experimental groups according to the cleaning method and restoration timing. Control group was not contaminated with the endodontic sealer and immediately restored (n=10). Cleaning protocols were cotton pellet soaked in saline (CPS) or cotton pellet soaked in 95% ethanol (CPE) or microbrush soaked in 95% ethanol (MBE). After removing of the sealer, a self-etching adhesive system was applied immediately (i) or delayed (d). The microtensile test applied and data were analyzed by Levene's, two way ANOVA and Tukey HSD statistical tests.

Results: There was no significant difference between the control group and the MBEd and CPSd groups ($p>0.05$). The bond strength of the CPSi, CPEi, CPEd, MBEi groups was statistically different from control ($p<0.05$) and there was no significant difference between these groups ($p>0.05$).

Conclusion: CPSd and the MBEd groups showed better microtensile bond strength values than other experimental groups.

Keywords: Root canal therapy, tensile strength, root canal sealents

INTRODUCTION

A combination of the gutta-percha and root canal sealer is generally used for root canal filling.[1] Root canal sealers are mainly responsible for filling irregularities in the prepared root canal walls as well as gap between gutta-percha and root canal walls.[2,3] Ensuring hermetically obturation prevent the root canal system from bacterial leakage apically or coronally and entomb residual microorganisms.[3,4] Also, residues of endodontic sealer in the pulp chamber can lead to dental discoloration and negatively affect bonding strength of adhesive system to hard tooth surfaces, hence, integrity of coronal seal is impaired, and the prognosis of the root-filled tooth is negatively affected.[5-9]

Adhesive materials generally maintain immediate seal and strengthening of the non-vital tooth, so they are preferred for restoration of the endodontically treated teeth.[7,10,11] So, the aim of this in vitro study was to evaluate influence of the different cleaning protocols on microtensile bond strength for dentin contaminated by the root canal sealers. Among endodontic sealers; epoxy resin based sealers, especially AH Plus (Densply), are generally preferred by clinicians as endodontic sealer[12] and used in various obturation techniques[13] for advantages like antimicrobial property, adequate working time, good sealability and easy handling.[14-16] So, our hypothesis is that after cleaning AH Plus with various methods, bond strength to dentin isn't decrease when immediately or delayed restoration.

METHODS

In this study, 7 intact human molars without cavities, extracted with patient consent during routine dental operations, were used. The study does not contain personal data, the study was conducted only on teeth in the laboratory. Therefore, it does not require ethics committee approval. All procedures were carried out in accordance with the ethical rules and the principles. Experimental groups consisted of three different cleaning methods and their combinations of immediate and delayed restoration timings. Cleaning protocols were cotton pellet soaked in saline (CPS) or cotton pellet soaked in 95% ethanol (CPE), microbrush soaked in 95% ethanol (MBE) and restoration timing protocols were immediately (i) and delayed (d).

This work is licensed under a Creative Commons Attribution 4.0 International License.

For the experimental groups, AH Plus (Dentsply) was prepared according to manufacturer's instructions and then placed over the exposed dentin as a thin layer. After 10 minutes applied sealer was set then CPS, CPE and MBE removal techniques were applied until the sealer on the dentine surface was unseen. After removing of the sealer, a self-etching adhesive system was applied immediately (i) or delayed (d).

For immediate groups (i) the surface was washed with water spray and air spray dried. A self-etching universal adhesive system (Prime&Bond; Dentsply) was applied to the dentin surface according to the manufacturer's instructions. After curing the adhesive agent with LED curing unit (VALO, Ultradent, Standard mode, 1000 mW/cm^2), resin composite material (Nova Compo B, Imicryl) with 4 mm thickness was placed using incremental technique on the adhesive applied dentin surface and cured with a same LED curing unit (VALO, Ultradent, Standard mode, 1000 mW/cm^2) according to the manufacturer's instructions.

For delayed restoration groups (d), the surface-cleaned teeth were kept in a petri dish containing moist cotton at 30°C for 72 hours. Then, the same restoration steps as in groups (i) were applied.

For the control group, AH Plus endodontic sealer was not applied to the dentin surface and immediate restoration was carried out.

The resin composite placed teeth were sectioned longitudinally, in mesio-distal then bucco-lingual direction using low-speed diamond saw under water cooling (Isomet; Buehler) to obtain beams that have approximate 1 mm^2 cross section area. 10 sticks were obtained from each group. The procedure for obtaining the sticks is summarized in **Figure 1**. The width (w) and length (l) of the beams were measured by electronic caliper (Starret 727-6/150; Starret) prior to the microtensile test to determine the bonding surface area more precisely. The beams are fixed to the microtensile test device (Bisco; Schaumburg) from their ends by cyanoacrylate resin glue, then subjected to a tensile force with speed of 1 mm/min. The force causing the failure was measured and noted in Newtons (N). The microtensile strength value by megapascal (MPa) of beams was calculated with the following formula:

After the microtensile test, specimens were removed from microtensile grip cautiously using a scalpel blade, and the fracture area of each beam was observed using a digital microscope (VHX-900F; Keyence) at × 40 magnification to classification of the fracture mode (adhesive, cohesive or mixed).

The sample size was calculated using G*Power software with 80% power, 0.05 α error probability and 0.4 effect size. Statistical analysis was performed with SPSS (IBM) software. Homogeneity of variances was evaluated with Levene's test, differences between groups were examined with two way ANOVA and post hoc Tukey HSD analyses. Probability value was accepted as 0.05.

RESULTS

A two-way ANOVA was performed to analyze the effect of cleaning protocol and restoration timing on microtensile bond strength. Both parameters have a statistically significant effect on microtensile bond strength and results given in **Table 1** ($p<0.01$). The arithmetic means of the microtensile values obtained from the tested groups was calculated and it was determined that the highest bond strength was in the control group that was not treated with AH plus and did not apply cleaning method. According to statistical analysis, it was determined that there was no significant difference between the control group and the MBEd and CPSd groups ($p>0.05$). The bond strength of the CPSi, CPEi, CPEd, MBEi groups was statistically different from control ($p<0.05$) and there was no significant difference between these groups ($p>0.05$). Box plot test data are shown in **Figure 2**. In the examination with the digital microscope of the separation surfaces of the beams after microtensile test, it was observed that all samples were subjected to adhesive failure.

Table 1. Two way ANOVA results

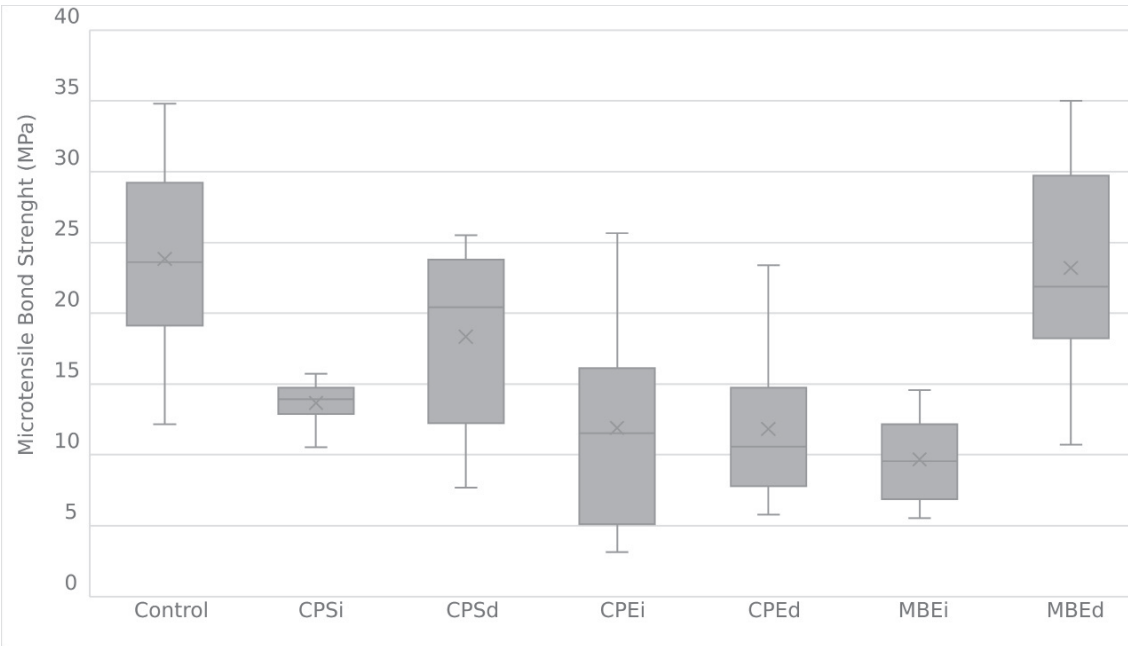

Figure 1. Obtaining sticks for microtensile test.

	Type III Sum of Squares	df	Mean Square	F	Sig.	Partial Eta Squared
Restoration timing	546.596	1	546.596	15.410	.000	.197
Cleaning protocol	1348.953	3	449.651	12.677	.000	.376
Restoration timing * cleaning protocol	476.386	2	238.193	6.715	.002	.176

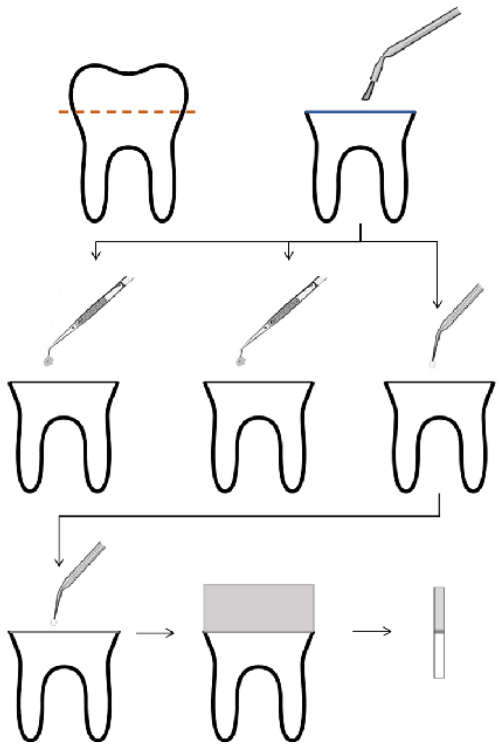

Figure 2. Mean microtensile bond strength of control and experimental groups.

The types of failure modes are presented in **Table 2**. Failure at the the adhesive interface occurred at all of the groups. However, cohesive failure was found only in the CPSi, CPEi, CPEd and MBEi groups.

Table 2. Fracture modes.

	Adhesive (%)	Cohesive (%)	Mix (%)
Control	50.00	0	50
CPSi	46.15	8	46
CPSd	90.00	0	10
CPEi	58.33	17	25
CPEd	87.50	13	0
MBEi	33.33	33	33
MBEd	50.00	0	50

DISCUSSION

In present study, influence of the different root canal sealer residue cleaning protocols on the bond strength to dentin investigated. So, our hypothesis is that after cleaning AH Plus with various methods, bond strength to dentin isn't decrease when immediately or delayed restoration was rejected. In order to test the bond strength, the microtensile method, which was stated to be reliable with previous studies, was chosen[17,18] and molar teeth were preferred because they have a large dentin surface that facilitates stick preparation.

Root canal treated teeth are weakened by caries and subsequent treatment procedures. For this reason, they are recommended to be restored quickly against the risk of fracture and coronal leakage.[19] Coronal leakage is the transport of bacteria, endotoxins, and oral fluids into the canal through the coronal opening as a result of loss of temporary filling material and poorly sealed permanent restorations. It's one of the major causes of endodontic failure.[20] These microleakages cause recurrent caries and apical periodontitis, which jeopardizes the success of both root canal and restorative treatment.[21,22] Clinicians can perform permanent restoration immediately after endodontic treatment or place temporary fillings to wait for confirmation of healing of apical periodontitis.[23,24] With the improvement in the techniques used in endodontic treatment (rubber dam use, magnifying devices, electronic apex locaters and motor-operated rotating files) the success rate of endodontic treatment has increased, and the time required for treatment has been shortened. Thus, single-session root canal treatments became possible. It has also been reported that there is no difference in the success rate and post-operatieve pain in the patient between single session or multi-session endodontic treatment.[25] But in our study, delayed restoration method generally had better dentin bonding strength than immediate restoration.

Clinically, after root canal treatment, the access cavity can be restored using a variety of methods, including direct and indirect restorations. Amalgam restorations, composite resin restorations, coronal-radicular restorations and post applications are conventional treatment methods that can be applied after root canal treatment.[26,27] Also, it has been shown that more harmonic stress distribution is achieved when materials that can be adhered to dental tissues. In addition, it has been reported that if the elasticity module of the restorative material is close to the dental tissues will reduce the stress occur in the remaining tooth tissues due to chewing forces. So, the most ideal restorative material for the restoration to be applied after root canal treatment is appears to be composite resin.[28] After obturation of the root canal system, self-etching adhesives are frequently used for providing a coronal sealing due to relatively easy to application and requiring less technical sensitivity.[29] Nevertheless, there is no chemical bond between epoxy-based resins and methacrylate-based resins and epoxy resin sealers that are not completely removed prior to coronal restoration may cause incomplete polymerization of monomers, bond deterioration, microleakage at the interface and coronal discoloration.[5,30,31] In vitro studies have been conducted with different cleaning methods and materials on the removal of endodontic sealers. The most studied model was dry cotton pellets and organic solvents. They are followed by mechanical drill refinement, air abrasion, microabrasion, ultrasound. It has been found that after cleaning using dry cotton pellets, the bond strength decreased to 69-88% of uncontaminated controls.[1,12,32-34] Alongside with numerous organic solvents, formamide provides high cleaning efficacy, but its potential teratogenicity has been noted in studies. Another solvent, acetone, affects the bond strength in a negative way because of collagen fiber collase.[35] In clinical practice, ethanol and distilled water is a routinely used solvent for surface cleaning

due to its easy accessibility. In present in-vitro study, the highest bonding was observed in the delayed-ethanol micropellet and delayed- wet cotton group (**Figure 2**). When using cotton pellets soaked with ethanol, it was observed that the immediate restoration provided a better bonding strength. Cleaning AH Plus contaminated dentin with ethanol-saturated cotton pellets appears to be ineffective for creating coronal seal with self-etching adhesives. In present study, the lowest adhesion was observed in the group in which ethanol was used with micropellet and immediately adhesive was applied. However, the highest bonding values were found with micropellet using ethanol and applying adhesive after 72 hours. The other group with high adhesion was the group that used distilled water-soaked cotton and applied adhesive after 72 hours. The reason for this is that maybe the after cleaning the Ah-Plus residues, the remaining residues completely set in the dentinal tubules and do not interfere the bonding agent during adhesive procedure.

As a limitation, effects of the presence of saliva in the oral environment, variable temperatures, mechanical fatigue, etc. were not evaluated due to lack of time and resources. In future randomized clinical trials of this subject may be beneficial.

CONCLUSION

Within the limitation of the present study, CPSd and the MBEd groups showed better bond strength values than other experimental groups. After root canal treatment, the bonding strength of the adhesive restoration to dentin can be increased with use of the effective sealer cleaning method and the application of adhesive restoration at the appropriate time.

ETHICAL DECLARATIONS

Ethic Committee Approval: In this study, 7 intact human molars without cavities, extracted with patient consent during routine dental operations, were used. The study does not contain personal data, the study was conducted only on teeth in the laboratory. Therefore, it does not require ethics committee approval.

Informed Consent: Since this study was conducted in the laboratory on 7 intact human molars without decay, extracted with patient consent during routine dental operations, it does not require informed consent.

Referee Evaluation Process: Externally peer-reviewed.

Conflict of Interest Statement: The authors have no conflicts of interest to declare. Financial Disclosure: The authors declared that this study has received no financial support.

Author Contributions: All of the authors declare that they have all participated in the design, execution, and analysis of the paper, and that they have approved the final version.

REFERENCES

1. Devroey S, Calberson F, Meire M. The efficacy of different cleaning protocols for the sealer-contaminated access cavity. *Clin Oral Investig.* 2020;24(11):4101-4107.
2. Hata G, Kawazoe S, Toda T, Weine FS. Sealing ability of Thermafil with and without sealer. *J Endod.* 1992;18(7):322-326.
3. Ørstavik D. Materials used for root canal obturation: technical, biological and clinical testing. *Endod Topics.* 2005;12(1):25-38.
4. Guttmann J, Witherspoon D. Obturation of the cleaned and shaped root canal system. In: Cohen S, Burns R, eds. Pathways of the Pulp. 8th ed. Mosby; 2002:293-364.
5. Parsons JR, Walton RE, Ricks-Williamson L. In vitro longitudinal assessment of coronal discoloration from endodontic sealers. *J Endod.* 2001;27(11):699-702.
6. Plotino G, Buono L, Grande NM, Pameijer CH, Somma F. Nonvital tooth bleaching: a review of the literature and clinical procedures. *J Endod.* 2008;34(4):394-407.
7. Yurdagüven H, Tanalp J, Toydemir B, Mohseni K, Soyman M, Bayirli G. The effect of endodontic irrigants on the microtensile bond strength of dentin adhesives. *J Endod.* 2009;35(9):1259-1263.
8. Rodríguez-Martínez JB, González-Rodríguez MP, González-López S, Ferrer-Luque CM. Influence of adhesive systems on microtensile bond strength of resin-based endodontic sealers to the root dentin. *J Clin Exp Dent.* 2014;6(3):203-208.
9. Bandeca MC, Kuga MC, Diniz AC, Jordão-Basso KC, Tonetto MR. Effects of the Residues from the Endodontic Sealers on the Longevity of Esthetic Restorations. *J Contemp Dent Pract.* 2016;17(8):615-617.
10. Ausiello P, De Gee A, Rengo S, Davidson C. Fracture resistance of endodontically-treated premolars adhesively restored. *Amer J Dent.* 1997;10(5):237-241.
11. Ree M, Schwartz RS. The endo-restorative interface: current concepts. *Dent Clin.* 2010;54(2):345-374.
12. Peters OA, Teo MR, Ooi JM, Foo AS, Teoh YY, Moule AJ. The effect of different sealer removal protocols on the bond strength of AH plus- contaminated dentine to a bulk- fill composite. *Aust Endod J.* 2020;46(1):5-10.
13. Vasiliadis L, Kodonas K, Economides N, Gogos C, Stavrianos C. Short- and long- term sealing ability of Gutta- flow and AH- Plus using an ex vivo fluid transport model. *Int Endod J.* 2010;43(5):377-381.
14. Heling I, Gorfil C, Slutzky H, Kopolovic K, Zalkind M, Slutzky-Goldberg I. Endodontic failure caused by inadequate restorative procedures: review and treatment recommendations. *J Prosthet Dent.* 2002;87(6):674-678.
15. Marin-Bauza GA, Abi Rached-Junior FJ, Souza-Gabriel AE, Sousa-Neto MD, Miranda CES, Silva-Sousa YTC. Physicochemical properties of methacrylate resin–based root canal sealers. *J Endod.* 2010;36(9):1531-1536.
16. Marciano MA, Guimarães BM, Ordinola-Zapata R, et al. Physical properties and interfacial adaptation of three epoxy resin–based sealers. *J Endod.* 2011;37(10):1417-1421.
17. Sano H, Shono T, Sonoda H, et al. Relationship between surface area for adhesion and tensile bond strength—evaluation of a micro-tensile bond test. *Dent Mater.* 1994;10(4):236-240.
18. Cardoso PEC, Sadek FT, Goracci C, Ferrari M. Adhesion testing with the microtensile method: effects of dental substrate and adhesive system on bond strength measurements. *J Adhes Dent.* 2002;4(4):291-297.
19. Taha NA, Messer HH. Restoration of the Root–Filled Tooth. *Prim Dent J.* 2016;5(2):29-35.
20. Ng YL, Mann V, Rahbaran S, Lewsey J, Gulabivala K. Outcome of primary root canal treatment: systematic review of the literature–Part 2. Influence of clinical factors. *Int Endod J.* 2008;41(1):6-31.
21. Muliyar S, Shameem KA, Thankachan RP, Francis P, Jayapalan C, Hafiz KA. Microleakage in endodontics. *J Int Oral Health.* 2014;6(6):99.
22. Gillen BM, Looney SW, Gu L-S, et al. Impact of the quality of coronal restoration versus the quality of root canal fillings on success of root canal treatment: a systematic review and meta-analysis. *J Endod.* 2011;37(7):895-902.
23. Chugal NM, Clive JM, Spångberg LS. Endodontic treatment outcome: effect of the permanent restoration. *Oral Surg Oral Med Oral Pathol Oral Radiol Endod.* 2007;104(4):576-582.
24. Safavi KE, Dowden WE, Langeland K. Influence of delayed coronal permanent restoration on endodontic prognosis. *Dent Traumatol.* 1987;3(4):187-191.
25. Wong AW-Y, Tsang CS-C, Zhang S, Li K-Y, Zhang C, Chu C-H. Treatment outcomes of single-visit versus multiple-visit non-surgical endodontic therapy: a randomised clinical trial. *BMC oral health.* 2015;15(1):1-11.
26. Carvalho MA, Lazari PC, Gresnigt M, Del Bel Cury AA, Magne P. Current options concerning the endodontically-treated teeth restoration with the adhesive approach. *Braz Oral Res.* 2018;32(suppl 1):e74.
27. Morgano SM, Rodrigues AH, Sabrosa CE. Restoration of endodontically treated teeth. *Dent Clin N Am.* 2004;48(2):397-416.
28. Zimmerli B, Strub M, Jeger F, Stadler O, Lussi A. Composite materials: composition, properties and clinical applications. A literature review. *Schweiz Monatsschr Zahnmed.* 2010;120(11):972-986.
29. Korasli D, Ziraman F, Ozyurt P, Cehreli SB. Microleakage of self-etch primer/adhesives in endodontically treated teeth. *J Am Dent Assoc.* 2007;138(5):634-640.
30. Peutzfeldt A, Asmussen E. Influence of eugenol-containing temporary cement on bonding of self-etching adhesives to dentin. *J Adhes Dent.* 2006;8(1):31-34.

31. Galvan Jr RR, West LA, Liewehr FR, Pashley DH. Coronal microleakage of five materials used to create an intracoronal seal in endodontically treated teeth. *J Endod*. 2002;28(2):59-61.
32. Roberts S, Kim JR, Gu L-s, et al. The efficacy of different sealer removal protocols on bonding of self-etching adhesives to AH Plus–contaminated dentin. *J Endod*. 2009;35(4):563-567.
33. Topçuoğlu HS, Demirbuga S, Pala K, Cayabatmaz M, Topçuoğlu G. The bond strength of adhesive resins to AH plus contaminated dentin cleaned by various gutta- percha solvents. *Scanning*. 2015;37(2):138-144.
34. Kuga MC, Faria G, Rossi MA, et al. Persistence of epoxy- based sealer residues in dentin treated with different chemical removal protocols. *Scanning*. 2013;35(1):17-21.
35. de Oliveira E, Cecchin D, Miyagaki DC, et al. Effect of different protocols of eugenol removal on the bond strength between the fibre post and root dentin. *Aust Endod J*. 2019;45(2):177-183.

Journal of Dental Sciences and Education

Review

DOI: 10.51271/JDSE-0016

Short dental implants

Meltem Karşıyaka Hendek, Kubilay Barış, Ebru Olgun

Department of Periodontology, Faculty of Dentistry Kırıkkale University, Kırıkkale, Turkey

Cite this article: Hendek MK, Barış K, Olgun E. Short dental implants *J Dent Sci Educ*. 2023;1(3):95-97.

Corresponding Author: Meltem Karşıyaka Hendek, mltmkrsyk@yahoo.com

Received: 22/09/2023 ◆ **Accepted**: 29/09/2023 ◆ **Published**: 30/09/2023

ABSTRACT

Short dental implants have been successfully used to support single and multiple fixed reconstructions in atrophic jaws, despite an increased crown-to-implant ratio. The use of short dental implants allows the treatment of patients for whom complex surgical techniques cannot be performed for medical, anatomical, or financial reasons. Furthermore, the use of short dental implants in clinical practice reduces morbidity, cost, and treatment time and reduces the need for complex surgery. The aim of this review is to evaluate the survival rates of short and extra-short dental implants and to discuss the impact of an increased crown-to-implant ratio on biologic and technical complications.

Keywords: Dental implants, implant-supported dental prosthesis, survival rate

INTRODUCTION

In dental implant treatment, excessively resorbed alveolar bone causes a serious problem during both the surgical and prosthetic phases.[1,2] Over the years, many surgical techniques have been developed to increase bone volume and enable implant placement. These techniques are essential for positioning long dental implants, achieving balanced load distribution, and improving the crown/implant ratio. Techniques such as maxillary sinus elevation, guided bone regeneration, distraction osteogenesis, and inferior alveolar nerve lateralization have been developed to place long dental implants in excessively resorbed alveolar bone. However, these complex surgical techniques are associated with complications such as intraoperative bleeding, perforation of the Schneiderian membrane or nerve damage, temporarily or permanently altered postoperative mandibular sensation, exposure of the graft or membranes, infections, and increased bone loss around the implant.[3] In addition to these complications, increased treatment time and cost, and the fact that advanced surgical techniques are not suitable for some patients for medical or anatomical reasons, alternative treatments are needed. In this context, the use of short dental implants should be considered as an alternative to complex surgeries. Short dental implants allow cheaper and faster treatment with a reduced morbidity rate as well as ease of application.[4] However, survival rates and indications are still controversial. Unfavorable crown/implant ratio, inadequate primary implant stability, and bone-implant contact have been described as reasons for the failure of short dental implants. The aim of this review is to evaluate the survival rates of short and extra-short dental implants and to discuss the impact of an increased crown-to-implant ratio on biologic and technical complications.

DISCUSSION

The length threshold defining a short dental implant is still a matter of debate in the scientific literature.[5] Some researchers consider this value to be <10 mm, while others define extra-short dental implants as <8 mm or even ≤6 mm.[6,7] Taschieri et al. (2018) compared the clinical and radiographic outcomes of 27 patients with short dental implants (6.5-8.5 mm) placed without any additional bone augmentation procedure in the posterior maxilla and 25 patients with standard implants (≥ 10 mm) placed in combination with lateral maxillary sinus floor elevation.[8] After a 72-month follow-up period, no significant differences were observed between the groups in terms of implant failure or changes in marginal bone level. In particular, the short dental implant group was reported to have less postoperative pain, inflammation, and other adverse postoperative effects, as well as faster healing compared to the other group.

In a retrospective study evaluating the performance of short dental implants (≤8 mm) based on different factors, including crown/implant ratio and prosthetic design (e.g., splinted vs. nonsplinted restorations), a total of 180 short dental implants placed in 130 patients were evaluated after 3-7 (mean=4.2) years of follow-up. It was reported that four implants in four different patients failed due to severe peri-implantitis, resulting in an overall cumulative survival rate of 97.8% at the implant level. Furthermore, the mean marginal bone loss was 0.90±0.78 mm. Most sites (70%) were shown to have a crown/implant ratio≥1 (mean=1.16±0.36). Correlation analyses revealed that sites with a crown/implant ratio <1 exhibited greater marginal bone loss (1.14±0.75 mm) compared to sites with ratios of 1-1.99 and ≥2 (0.81±0.77 mm and 0.45±0.47 mm, respectively). It was also observed that peri-implant bone loss and complication rates were not statistically different between splinted and non-splinted prostheses.[9]

This work is licensed under a Creative Commons Attribution 4.0 International License.

Another retrospective study evaluated the performance of short dental implants (<8 mm) in posterior maxillary and mandibular partially edentulous regions. Data were obtained from the medical records of 148 patients treated with a total of 225 short dental implants between 2005 and 2014, following an observation period of up to 14 years in clinical function, and outcomes such as implant stability, marginal bone loss, and success/survival rates were evaluated. The results of this comprehensive retrospective study revealed an overall success and retention rate of 93.33% and 97.78%, respectively. Cumulative 5- and 10-year survival rates were 99.05% and 96.72%, respectively; mean marginal bone loss was 0.43 mm.[10]

A 2014 Cochrane systematic review and meta-analysis presented four clinical trials evaluating short dental implants (5 to 8.5 mm in length) as an alternative to maxillary sinus floor elevation in areas with residual bone height between 4-mm and 9-mm.[11] One year after loading, there was insufficient evidence to indicate differences between the two procedures in terms of prosthesis (OR=0.37) or implant failure (OR=0.44). However, a higher risk of complications (e.g., infection, bleeding, nerve injury, etc.) has been reported at sites where maxillary sinus floor elevation surgery was performed (OR=4.77).

As part of the 2015 European Association for Osseointegration (EAO) consensus conference, a systematic review was conducted on the performance of short dental implants (≤8 mm) compared to conventional implant placement with maxillary sinus floor elevation.[12] The results of a total of 8 randomized controlled trials published between 1990 and 2014 showed that short dental implants achieved survival rates comparable to standard-length implants placed in combination with maxillary sinus floor elevation (98.0%-99.2% for short dental implants and 99.5%-99.0% for standard-length implants). However, the incidence of complications (Schneiderian membrane perforation) was reported to be three times higher with maxillary sinus floor elevation, resulting in increased morbidity, prolonged healing times, and increased financial expenditure.

In a systematic review of 10 randomized controlled clinical trials comparing long (>6 mm) and short (≤6 mm) dental implants placed in posterior edentulous sites, data from 637 short dental implants and 653 standard-length implants placed in 775 patients were evaluated. In terms of retention rate, short dental implants were found to be associated with higher variability and lower predictability compared to long dental implants after function periods of 1-5 years. However, the mean reported retention rate was 96% (range: 86.7%-100%) for short dental implants and 98% (range: 95%-100%) for longer dental implants.[13]

Regarding extra-short dental implants (≤6 mm), a systematic review and meta-analysis of a total of 24 clinical trials, including 657 dental implants with a maximum follow-up of 5 years, reported that single crowns supported with extra-short dental implants exhibited a similar risk of failure to those supported with conventional dental implants, regardless of the history of maxillary sinus floor elevation, with a cumulative failure rate of [5.19] %. It was also noted that biologic complications were more frequent than biomechanical/prosthetic complications.[14]

Only a few descriptive studies have evaluated the effect of the crown/implant ratio on peri-implant bone loss15-19, implant survival rate.[16,18,20] or the occurrence of biological and technical complications.[18] Among this group of publications, three studies.[15,18,20] included only single-tooth implant-supported restorations, thus avoiding the bias of better occlusal force distribution in studies[16,17,19] that included mainly splinted implant restorations. Three studies showed that marginal bone loss was not related to the crown/implant ratio,[15,18,19] while two studies showed that implant restorations with higher crown/implant ratios exhibited statistically lower marginal bone loss compared to implant restorations with lower crown/implant ratios.[16,17] According to Blanes et al.[16], this may be explained by the stimulating nature of bone stress.

Similar survival rates have been reported for implant restorations with high and low crown/implant ratios.[16,18,20] Furthermore, the crown/implant ratio was found to have no statistically significant effect on the occurrence of biologic and technical complications.[18] These results are in agreement with the results of another systematic review that evaluated the effect of the crown-to-implant ratio on the survival and complication risk of implant-supported reconstructions.[21] It should be noted that most implant-supported restorations have crown-to-implant ratios between 1.0 and 2.0, with little data available for crown-to-implant ratios>2.0. Therefore, the effect of crown-to-implant ratios>2.0 on marginal bone loss should be investigated in more studies.

CONCLUSION

Short dental implants can be successfully used to support single and multiple reconstruction of the atrophic jaw, even with increasing crown-to-implant ratios. The use of short dental implants allows the treatment of patients for whom complex surgical techniques are not feasible for medical, anatomical, and financial reasons. For such patients, the decision may be whether to undergo a short dental implant-supported fixed reconstruction, a removable prosthesis, or a long-fixed reconstruction. Moreover, the use of short dental implants in clinical practice reduces the need for complex surgery and, therefore, morbidity, cost, and treatment time. However, longer observation periods of up to 10 years (for both case series and randomized controlled trials) are needed. Additional studies should also investigate the crown/implant effect of a>2.0 ratio and the possibility of using extra-short dental implants.

ETHICAL DECLARATIONS

Referee Evaluation Process: Externally peer-reviewed.

Conflict of Interest Statement: The authors have no conflicts of interest to declare.

Financial Disclosure: The authors declared that this study has received no financial support.

Author Contributions: All of the authors declare that they have all participated in the design, execution, and analysis of the paper, and that they have approved the final version.

REFERENCES

1. Chaushu G, Taicher S, Halamish-Shani T, Givol N. Medicolegal aspects of altered sensation following implant placement in the mandible. *Int J Oral Maxillofac Implants.* 2002;17(3):413-415.
2. Friberg B. The posterior maxilla: clinical considerations and current concepts using Branemark System implants. Periodontol 2000. 2008;47(1):67-78.

3. Esposito M, Grusovin MG, Felice P, Karatzopoulos G, Worthington HV, Coulthard P. The efficacy of horizontal and vertical bone augmentation procedures for dental implants – a Cochrane systematic review. *Eur J Oral Implantol.* 2009;2(3):167-184.
4. Esposito M, Pellegrino G, Pistilli R, Felice P. Rehabilitation of posterior atrophic edentulous jaws: prostheses supported by 5 mm short implants or by longer implants in augmented bone? One-year results from a pilot randomised clinical trial. *Eur J Oral Implantol.* 2011;4(1):21-30.
5. Nisand D, Renouard F. Short implant in limited bone volume. *Periodontol 2000.* 2014;66(1):72- 96.
6. Ravida A, Barootchi S, Askar H, Suarez-Lopez Del Amo F, Tavelli L, Wang HL. Long-term effectiveness of extra-short (≤6 mm) dental implants: a systematic review. *Int J Oral Maxillofac Implants.* 2019; 34(1):68-84.
7. Al-Sawaf O, Tuna T, Rittich A, Kern T, Wolfart S. Randomized clinical trial evaluating the effect of splinting crowns on short implants in the mandible 3 years after loading. *Clin Oral Implants Res.* 2020;31(11):1061-1071.
8. Taschieri S, Lolato A, Testori T, Francetti L, Del Fabbro M. Short dental implants as compared to maxillary sinus augmentation procedure for the rehabilitation of edentulous posterior maxilla: three-year results of a randomized clinical study. *Clin Implant Dent Relat Res.* 2018;20(1):9-20.
9. Tang Y, Yu H, Wang J, Gao M, Qiu L. Influence of crown-to-implant ratio and different prosthetic designs on the clinical conditions of short implants in posterior regions: a 4-year retrospective clinical and radiographic study. *Clin Implant Dent Relat Res.* 2020;22(1):119-127.
10. Ku JK, Kim IH, Lee JG, Kim YK. Long-term clinical evaluation of short implants on posterior partially edentulous areas: a 14-year retrospective study. *Int J Oral Maxillofac Implants.* 2021;36(1):131-136.
11. Esposito M, Felice P, Worthington HV. Interventions for replacing missing teeth: augmentation procedures of the maxillary sinus. *Cochrane Database Syst Rev.* 2014;13(5):CD008397.
12. Thoma DS, Zeltner M, Husler J, Hammerle CH, Jung RE. EAO Supplement Working Group 4 – EAO CC 2015 short implants versus sinus lifting with longer implants to restore the posterior maxilla: a systematic review. *Clin Oral Implants Res.* 2015;26(Suppl 11):154-169.
13. Papaspyridakos P, De Souza A, Vazouras K, Gholami H, Pagni S, Weber HP. Survival rates of short dental implants (≤6 mm) compared with implants longer than 6 mm in posterior jaw areas: a meta-analysis. *Clin Oral Implants Res.* 2018;29(Suppl 16):8-20.
14. Badaro MM, Mendoza Marin DO, Pauletto P, Simek Vega Goncalves TM, Porporatti AL, De Luca Canto G. Failures in single extra-short implants (≤6 mm): a systematic review and metaanalysis. *Int J Oral Maxillofac Implants.* 2021;36(4):669-689.
15. Birdi H, Schulte J, Kovacs A, Weed M, Chuang SK. Crown to-implant ratios of short-length implants. *J Oral Implantol.* 2010;36:425-433.
16. Blanes RJ, Bernard JP, Blanes ZM, Belser UC. A 10-year prospective study of ITI dental implants placed in the posterior region II: Influence of the crown to implant ratio and different prosthetic treatment modalities on crestal bone loss. *Clin Oral Implants Res.* 2007;18(6):707-714
17. Rokni S, Todescan R, Watson P, Pharoah M, Adegbembo AO, Deporter D. An assessment of crown-to-root ratios with short sintered porous-surfaced implants supporting prostheses in partially edentulous patients. *Int J Oral Maxillofac Implants.* 2005;20(1):69-76.
18. Schneider D, Witt L, Hammerle CH. Influence of the crown-to-implant length ratio on the clinical performance of implants supporting single crown restorations: a cross-sectional retrospective 5-year investigation. *Clin Oral Implants Res.* 2012;23(2):169-174.
19. Tawil G, Aboujaoude N, Younan R. Influence of prosthetic parameters on the survival and complication rates of short implants. *Int J Oral Maxillofac Implants.* 2006;21(2):275-282.
20. Schulte J, Flores AM, Weed M. Crown-to-implant ratios of single tooth implant-supported restorations. *J Prosthet Dent.* 2007;98(1):1-5.
21. Blanes RJ. To what extent does the crown-implant ratio affect the survival and complications of implant-supported reconstructions? A systematic review. *Clin Oral Implants Res.* 2009;20(Suppl 4):67-72.

Journal of Dental Sciences and Education

Review

DOI: 10.51271/JDSE-0017

Gingival crevicular fluid and peri-implant sulcus fluid

Ebru Olgun, Meltem Karşıyaka Hendek, Kubilay Barış,

Department of Periodontology, Faculty of Dentistry Kırıkkale University, Kırıkkale, Turkey

Cite this article: Olgun E, Karşıyaka Hendek M, Barış K. Gingival crevicular fluid and peri-implant sulcus fluid. *J Dent Sci Educ*. 2023;1(3):95-100.

Corresponding Author: Ebru Olgun, olgun_ebru@yahoo.com

Received: 22/09/2023 ◆ **Accepted**: 29/09/2023 ◆ **Published**: 30/09/2023

ABSTRACT

Gingival crevicular fluid (GCF) is an important source for the assessment of periodontal and peri-implant disease activity and response to periodontal therapy. GCF contains cellular components such as epithelium, bacteria, leukocytes, erythrocytes, viruses and their by-products, electrolytes, bacterial metabolic products, host and bacterial enzymes, and enzyme inhibitors such as acid phosphatase, alkaline phosphatase, cytokines, and immunoglobulins. In addition, it is also found that drugs taken systemically pass into the GCF.

Keywords: Gingival crevicular fluid, peri-implant sulcus fluid

INTRODUCTION

Tissue color, contour, presence of bleeding on probing (BOP), gingival recession, pocket depth (PD), clinical attachment level (CAL), suppuration, and tooth mobility are considered in the diagnosis and evaluation of diseases affecting the periodontium.[1] Radiographs contribute to the diagnosis by showing bone loss around the teeth.[2] However, these techniques only determine past disease activity. Reliable diagnostic methods are required to evaluate disease activity and response to periodontal treatment.[3]

Gingival groove fluid (GCF) is defined as serum transudate when the periodontium is healthy and the inflammatory exudate of periodontal tissues in disease. Exudate is the result of increased permeability of the vessels adjacent to the junctional epithelium and leakage of plasma into the sulcus.[4] Transudate is the result of increased pressure in veins and capillaries, which causes the interstitial fluid to pass through the vessel wall into the sulcus.[5,6] In terms of content, transudate is a protein-poor, watery interstitial fluid, whereas exudate is a more protein-rich structure, including essential plasma proteins and immunologically active components.

Since the early 1960s, it has been suggested that biochemical analysis of GCF may be an effective method for assessing the inflammatory status of gingival tissues.[7,8,9,10] In a human experimental model of gingival inflammation, it has been shown that signs of inflammation are observed when oral hygiene practices are interrupted for three days and that GCF synthesis accompanies clinical signs of inflammation, such as bleeding on probing11. Therefore, GCF is an important source for periodontal disease activity and for evaluating the effectiveness of periodontal therapy.

GCF contains cellular components such as epithelium, bacteria, leukocytes erythrocytes, erythrocytes, viruses and their products.[12,13,14], electrolytes[9,15], bacterial metabolic products[16], host and bacterial enzymes, and enzyme inhibitors such as acid phosphatase, alkaline phosphatase[17], cytokines[18,19,20] and immunoglobulins.[21,22] It has also been found that systemically administered drugs pass into the GCF.[23,24,25]

Gingival Crevicular Fluid Collection Methods

Three basic methods for obtaining GCF have been described[4];

- Capillary tube method
- Gingival sulcus washing method
- Paper strip method
- Capillary tube method

The use of micropipettes allows the collection of fluid through capillary activity. Capillary tubes are inserted into a pocket of standard length and diameter, and the contents are then centrifuged and analyzed.[7,26] After isolation and drying of the area of interest, capillary tubes are placed at the entrance of the gingival groove. The GCF in the sulcus moves towards the tube with capillary activity. By measuring the distance, the GCF moves, the volume collected can be determined.[27] This technique is especially used in individuals with periodontal disease, in whom an increase in GCF volume is expected. An important disadvantage of this method is that the tubes placed in the sulcus and moved in this area may cause trauma.

Gingival Sulcus Washing Method

This method has been applied in two different ways. The basic approach in both applications is to wash the gingival

This work is licensed under a Creative Commons Attribution 4.0 International License.

sulcus with a certain amount of fluid and collect this fluid again. In the first application, the sample area isolated with rolled cottons is washed with a special solution, and the GCF and the fluid delivered to the area are collected with a micro syringe.[4,28,29,30] As a result, the volume and content of the GCF sample obtained may not be accurate.[4] In the other application, acrylic plates containing tubes are prepared specifically for the individual. After washing the gingival groove, GCF and fluid are collected with the tubes in the plates.[30] However, the preparation of individualized plates is a factor limiting the use of this method. In addition, there is a risk of contamination in the lower jaw with both methods.[4]

Paper Strip Method

In this method, paper strips are used to obtain GCF. The technique, which is divided into in-groove and out-of-groove, is the most commonly used GCF collection method today. In the out-of-groove method, the paper strip is placed on the buccal surface of the tooth, close to the sulcus entrance.[9] Due to the position of the paper strip, the possibility of contamination is high.[9] In the in-groove method, the paper strip is advanced until resistance is felt in the sulcus, and the GCF sample is obtained from the sulcus in this way.[20,31,32] However, prolonged sampling time increases the risk of mechanical irritation and contamination.[9,31]

Determination of Gingival Crevicular Fluid Volume by Paper Strip Method

Following GCF collection with paper strips, there are different approaches to determining the volume of fluid obtained.

Microscopic Examination of Wet Areas on Paper Strips

In this GCF volume determination method, the wet area on a paper strip with a known surface area is calculated. The collected strips are stained with ninhydrin, and the wet areas are determined under a microscope.[4,9,33,34,35] In addition, a systemically administered fluorescent dye can be extracted from the gingival sulcus, and the wet areas of GCF samples collected on paper strips can be examined under ultraviolet light.[4,36]

In addition to the difficulty of performing this method at the bedside, there is also the possibility of loss of samples by evaporation before examination.[4]

Weighing Paper Strips

This method is based on weighing paper strips on a precision balance before and after obtaining GCF samples. Even with this method, the volume of GCF can change with evaporation.[4]

Determination of Gingival Crevicular Fluid Volume with Periotron Device

Currently, the Periotron device (Periotron 8000, Oraflow Inc., Plainville, NY, USA) is most commonly used to determine GCF volume. In this fast and sensitive technique, the volume of GCF in paper strips is determined by electrical capacitance changes.[4] For the calibration of the device, liquids with known volumes are applied to paper strips and read by the periotron device, and a calibration curve is obtained as a result. According to this curve, the GCF volume is determined.[37] Factors such as the calibration of the periotron device, the properties of the paper strips used, contamination of the device and the sampling area, evaporation, temperature, and humidity of the environment may affect the determination of the GCF volume.[38]

Factors Affecting the Amount of Gingival Crevicular Fluid

The amount of GCF is higher in the presence of inflammation and increases in proportion to the severity of inflammation.[39,34] Chewing hard foods, tooth brushing, and gingival massage also stimulate GCF flow.[40] Circadian rhythm.[41], sex hormones, and fixed prosthetic restorations have also been reported to increase GCF.[42] Although smoking causes a transient increase in GCF flow, GCF flow decreases in the long term.[43] An increase is also observed during the healing period after periodontal surgery.[44] These factors should be taken into consideration in order to make healthy measurements in GCF acquisition.

Peri-implant Sulcus Fluid

Early and accurate diagnosis of peri-implant diseases is one of the factors that help to prolong the life of dental implants.[45] Different factors, including clinical, biochemical, and microbiological parameters, are used to assess the health of the tissues around the implant and to make an early diagnosis. These factors include peri-implant probing depth, bleeding on probing, suppuration, biochemical analysis of peri-implant sulcus fluid or saliva, microbiological analysis of peri-implant microbiota, and radiographic evaluation of peri-implant bone levels. Peri-implant sulcus fluid (PISF) is a serum-derived, osmotically mediated exudate originating from the gingival vascular plexus and is considered being an analog of the GCF of natural teeth.[46] The contents of GCF and PISF are similar, containing substances from microorganisms in the subgingival and supragingival plaque along with the host.[17] The difference in biomarkers and enzymes in the peri-implant sulcus fluid during the transition from health to disease state provides promising results.[47] In the presence of inflammation, the volume of PISF increases. This is because inflammatory mediators, tissue degradation products, and mineralized tissue components pass into the PISF during inflammation.

PISF has been used in the diagnosis of peri-implant inflammation.[46] Although not widely used in practical applications, PISF analysis is a promising and reliable diagnostic tool.[45]

CONCLUSION

The greatest appeal of GCF as a diagnostic marker is the site-specific nature of the sample. This allows for the correlation of GCF components with clinical assessments. Understanding the components of GCF, including cellular elements, will help to clarify the initial events in the pathogenesis of periodontal and peri-implant diseases and to monitor the disease process. It will also enable new, effective treatment paradigms and strategies to prevent periodontal and peri-implant diseases.

ETHICAL DECLARATIONS

Referee Evaluation Process: Externally peer-reviewed.

Conflict of Interest Statement: The authors have no conflicts of interest to declare.

Financial Disclosure: The authors declared that this study has received no financial support.

Author Contributions: All of the authors declare that they have all participated in the design, execution, and analysis of the paper, and that they have approved the final version.

REFERENCES

1. Buduneli N, Kinane DF. Host- derived diagnostic markers related to soft tissue destruction and bone degradation in periodontitis. *J Clin Periodontol*. 2011;38 Suppl 11:85-105.
2. Brägger U. Radiographic parameters: biological significance and clinical use. *Periodontol 2000*. 2005;39(1):73-90.
3. Loos BG, Tjoa S. Host- derived diagnostic markers for periodontitis: do they exist in gingival crevice fluid? *Periodontol 2000*. 2005;39(1):53-72.
4. Griffiths GS. Formation, collection and significance of gingival crevice fluid. *Periodontol 2000*. 2003;31(1):32-42.
5. Del Fabbro M, Francetti L, Bulfamante G, *et al*. Fluid dynamics of gingival tissues in transition from physiological condition to inflammation. *J Periodontol*. 2001;72(1):65-73.
6. Pashley DH. A mechanistic analysis of gingival fluid production. *J Periodontal Res*. 1976;11(2):121-134.
7. Brito F, Curcio HFQ, da Silva Fidalgo TK. Periodontal disease metabolomics signatures from different biofluids: a systematic review. *Metabolomics*. 2022;18(11):83.
8. Baima G, Corana M, Iaderosa G, *et al*. Metabolomics of gingival crevicular fluid to identify biomarkers for periodontitis: A systematic review with meta-analysis. *J Periodontal Res*. 2021;56(4):633-645.
9. Almehmadi AH, Alghamdi F. Biomarkers of alveolar bone resorption in gingival crevicular fluid: A systematic review. *Arch Oral Biol*. 2018;93:12-21.
10. Bostanci N, Belibasakis GN. Precision periodontal care: from omics discoveries to chairside diagnostics. *Clin Oral Investig*. 2023;27(3):971-978.
11. Loe H, Holm-Pedersen P. Absence and presence of fluid from normal and inflamed gingiva. *Periodontics*. 1965;149:171-177.
12. Maulani C, Auerkari EI, C Masulili SL, Soeroso Y, Djoko Santoso W, S Kusdhany L. Association between Epstein-Barr virus and periodontitis: A meta-analysis. *PLoS One*. 2021;16(10):e0258109.
13. Maticic M, Poljak M, Kramar B. Proviral HIV–1 DNA in gingival crevicular fluid of HIV–1– infected patients in various stages of HIV disease. *J Dent Res*. 2000;79(7):1496-1501.
14. Delima AJ, Van Dyke TE. Origin and function of the cellular components in gingival crevice fluid. *Periodontol* 2000;31(1):55-76.
15. Bartold PM, Narayanan AS. Biology of the Periodontal Connective Tissues Quintessence Publishing Co, Illinois–USA, 1998;223-240.
16. Phillips L, Chu L, Kolodrubetz D. Multiple enzymes can make hydrogen sulfide from cysteine in Treponema denticola. *Anaerobe*. 2020;64:102231.
17. Lamster IB, Ahlo JK. Analysis of gingival crevicular fluid as applied to the diagnosis of oral and systemic diseases. *Ann N Y Acad Sci*. 2007;1098(1):216-229.
18. Prathapan Santhakumari P, Varma Raja V, Joseph J, Devaraj A, John E, Oommen thomas n. impact of low-level laser therapy on orthodontic tooth movement and various cytokines in gingival crevicular fluid: a split-mouth randomized study. *Cureus*. 2023;15(8):e42809.
19. Sumbayak IA, Masulili SLC, Tadjoedin FM, *et al*. Changes in interleukin-1β, tumor necrosis factor-α, and interleukin-10 cytokines in older people with periodontitis. *Geriatrics (Basel)*. 2023;8(4):79.
20. Oliveira JA, de Oliveira Alves R, Nascimento IM, Hidalgo MAR, Scarel-Caminaga RM, Cristina Pigossi S. Pro- and anti-inflammatory cytokines and osteoclastogenesis-related factors in peri-implant diseases: systematic review and meta-analysis. *BMC Oral Health*. 2023;23(1):420.
21. Peskersoy C, Oguzhan A, Gurlek O. The effect of flowable composite resins on periodontal health, cytokine levels, and immunoglobulins. *Biomed Res Int*. 2022;2022:6476597.
22. Moriya Y, Obama T, Aiuchi T, *et al*. Quantitative proteomic analysis of gingival crevicular fluids from deciduous and permanent teeth. *J Clin Periodontol*. 2017;44(4):353-362.
23. Heasman PA, Ward A, Barrett AW, Seymour RA, Edwards G. Flurbiprofen in human crevicular fluid analyzed by high-performance liquid chromatography. *J Periodontal Res*. 1990;25(2):88-92.
24. Mclaughlin WS, Ball DE, Seymour RA, Kamali F, White K. The pharmacokinetics of phenytoin in gingival crevicular fluid and plasma in relation to gingival overgrowth. *J Clin Periodontol*. 1995;22(12):942-945.
25. Sakellari D, Goodson JM, Socransky SS, Kolokotronis A, Konstantinidis A. Concentration of 3 tetracyclines in plasma, gingival crevice fluid and saliva. *J Clin Periodontol*. 2000;27(1):53-60.
26. Björn AL, Koch G, Lindhe J. Evaluation of gingival fluid measurements. *Odontol Revy*. 1965;16(4):300-307.
27. Sueda T, Bang J, Cimasoni G. Collection of gingival fluid for quantitative analysis. *J Dent Res*. 1969;48(1):159.
28. Skapski H, Lehner T. A crevicular washing method for investigating immune components of crevicular fluid in man. *J Periodontal Res*. 1976;11(1):19-24.
29. Challacombe SJ, Russell MW, Hawkes J. Passage of intact IgG from plasma to the oral cavity via crevicular fluid. *Clin Exp Immunol*. 1978;34(3):417-422.
30. Oppenheim FG. Preliminary observations on the presence and origin of serum albumin in human saliva. *Helv Odontol Acta*. 1970;14(1):10-17.
31. Özkavaf A, Aras H, Huri CB. Analysis of factors that may affect the enzymatic profile of gingival crevicular fluid: sampling technique, sequential sampling and mode of data presentation. *J Oral Sci*. 2001;43(1):41-48.
32. Majeed ZN, Philip K, Alabsi AM, Pushparajan S, Swaminathan D. Identification of gingival crevicular fluid sampling, analytical methods, and oral biomarkers for the diagnosis and monitoring of periodontal diseases: a systematic review. *Dis Markers*. 2016;2016:1804727.
33. Hancock EB, Cray J, O'leary J. Relationship between gingival crevicular fluid and gingival inflammation: a clinical and histologic study. *J Periodontol*. 1979;50(1):13-19
34. Caldeira FID, Hidalgo MAR, Dias MLC, Scarel-Caminaga RM, Pigossi SC. Systematic review of ratios between disease /health periodontitis modulators and meta-analysis of their levels in gingival tissue and biological fluids. *Arch Oral Biol*. 2021;127:105147.
35. Sorensen SE, Larsen IB, Jörgensen KD. Gingival and alveolar bone reaction to marginal fit of subgingival crown margins. *Scand J Dent Res*. 1986;94(2):109-114.
36. Weinstein E, Mandel I, Salkind A, Oshrain HI, Pappas GD. Studies of gingival fluid. *Periodontics*. 1967;5:161-166.
37. Ciantar M, Caruana DJ. Periotron 8000: Calibration characteristics and reliability. *J Periodontal Res*. 1998;33(5):259-264.
38. Hatipoğlu H. Potential factors which affect gingival crevicular fluid sampling procedures. *EÜ Dişhek Fak Derg,* 2010;31:69-81.
39. Garnick JJ, Pearson R, Harrell D. The evaluation of the Periotron. *J Periodontol*. 1979;50(8):424-426.
40. LindhE J, Attstrom R, Bjorn AL. Influence of sex hormones on gingival exudate of gingivitis-free female dogs. *J Periodontal Res*. 1968;3(4):273-278
41. Bissada NF, Schaffer EM, Haus E. Circadian periodicity of human crevicular fluid. *J Periodontol*. 1967;38(1):36-40.
42. Nagao M. Influence of prosthetic appliances upon the flow of crevicular tissue fluid. I. Relation between crevicular tissue fluid and prosthetic appliances. *Bull Tokyo Med Dent Univ*. 1967;14:241.
43. Dutra TP, Sacramento CM, Nagay BE, *et al*. Do smokers have a different gingival crevicular fluid cytokine/chemokine profile than nonsmokers in clinically healthy periodontal sites? A systematic review and meta-analysis. *Clin Oral Investig*. 2022;26(2):1183-1197.
44. Koidou VP, Chatzopoulos GS, Tomas I, Nibali L, Donos N. Expression of gingival crevicular fluid markers during early and late healing of intrabony defects after surgical treatment: a systematic review. *Clin Oral Inves*tig. 2020;24(1):487-502.
45. Janska E, Mohr B, Wahl G. Correlation between peri-implant sulcular fluid rate andexpression of collagenase 2 (MMP8). *Clin Oral Investig*. 2016;20(2):261-266.
46. Javed F, Al-Hezaimi K, Salameh Z, Almas K, Romanos GE. Proinflammatory cytokines in the crevicular fluid of patients with peri-implantitis. *Cytokine*. 2011;53(1):8-12.
47. Dursun E, Tözüm TF. Peri-Implant Crevicular Fluid Analysis, Enzymes and Biomarkers: a Systematic Review. J Oral Maxillofac Res. 2016;7(3):e9.